Reprinted from the Archives of Otolaryngology--Head & Neck Surgery April, 1997 Volume 123

ORIGINAL ARTICLE

The Management of Hyperfunctional Facial Lines With Botulinum Toxin

A Collaborative Study of 210 Injection Sites in 162 Patients

Andrew Blitzer, MD, DDS; William J. Binder, MD; Jonathan E. Aviv, MD; Monte S. Keen, MD; Mitchell F. Brin, MD

Objective: To determine the optimum dose and efficacy of botulinum toxin injections in the management of hyperfunctional facial lines.

Design: This study included 210 hyperfunctional facial sites in 162 different patients. The patients had preinjection and postinjection photographic documentation and ratings on a 4-point qualitative evaluation scale of lines at rest and with action. The patients then had botulinum toxin type A injections via a monopolar hollow bore, Teflon-coated electromyographic needle into the facial muscles associated with the hyperfunctional lines. The total dose for each region of 1.25 to 25 U was divided into 1.25- to 5-U aliquots representing 0.1 to 0.2 mL per injection site, depending on the site and the prior experience with that patient on using toxin. The patients had their reevaluation at 2 to 3 weeks after injection. Patients returned for further follow-up when the therapeutic effect diminished.

Patients: One hundred sixty-two patients had 210 hyperfunctional sites evaluated and injected. The group consisted of 25 male patients and 137 female patients ranging in age from 21 to 78 years with a mean (±SD) of 46.1 (±1.98) years. All patients had cosmetically troubling hyperfunctional lines involving the forehead, glabella, crow's feet (lateral canthal lines), nasolabial area, platysma, and mentalis region.

Results: All patients had an effect of toxin within the first 24 to 72 hours. Ninety-five percent of the patients treated had cosmetic improvement of unsightly facial lines or contractions. The best results were achieved in management of the forehead lines, followed by glabella, crow's feet, and nasolabial. The dose for forehead lines was 5 to 25 U (mean±SD, 17.3±6.2 U); glabellar lines, 5 to 20 U (mean±SD, 11.1±3.1 U); crow's feet, 5 to 15 U (mean±SD, 6.2±1.6 U); nasolabial, 2.5 to 5 U (mean±SD, 3.12±1.2 U); and platysma, 10 to 20 (mean±SD, 15±4.0 U). Evaluation by age and site suggested a trend of increased toxin dose with increased age. Effects of the toxin are usually seen 24 to 72 hours after injection, and last from 3 to 6 months, whereon the increased muscular activity returns, as do the hyperfunctional lines. The only morbidity was related to temporary mild weakness of other adjacent facial muscles. There were no systemic side effects noted.

Conclusion: Botulinum toxin is a safe and important adjunctive technique for the management of patients with symptomatic hyperfunctional facial lines.

Arch Otolaryngol Head Neck Surg. 1997;123:389-392

From the Head and Neck Surgical Group, New York, NY (Dr Blitzer); Division of Head and Neck Surgery, University of California, Los Angeles (Dr Binder); and Department of Neurology, Mt Sinai Medical Center (Dr Brin), and Department of Otolaryngology, Columbia–Presbyterian Medical Center (Drs Keen and Aviv), New York, NY.

SINCE 1984 we have treated more than 1500 patients with focal dystonias using botulinum toxin type A and have published our experience with these patients who have blepharospasm, torticollis, oromandibular dystonia, adductor and abductor laryngeal dystonia, lingual dystonia, limb dystonia, and hemifacial spasm.[1-12]

We have previously reported success in the reduction of hyperfunctional facial lines using botulinum toxin type A injections in patients who have blepharospasm, Meige syndrome involving the upper and/or lower parts of the face, hemifacial spasm, and post–Bell palsy facial synkinesis.[13] We also reported statistically significant efficacy using botulinum toxin type A for hyperfunctional facial lines in a placebo-controlled, double-blind study, as well as the cosmetic effects of botulinum toxin in limited studies.[14,15] Carruthers and Carruthers[16] also described the therapeutic efficacy for management of wrinkles. Based on these previous studies, we devised a collaborative study of 2 institutions to evaluate the effect of dose, age, site, and complications on the successful diminution of hyperfunctional facial lines in a large cohort of patients.

PATIENTS, MATERIALS, AND METHODS

BOTULINUM TOXIN

Botulinum toxin is produced by the bacterium *Clostridium botulinum*. Eight serologically distinct toxins designated A, B, C1, C2, D, E, F, and G have been described.[17] Botulinum toxin exerts its effect at the neuromuscular junction by inhibiting the release of acetylcholine, and this in turn causes weakness or flaccid paralysis. Pharmacological and morphological studies suggest the toxin enters the nerve ending via a receptor-mediated endocytosis. This process appears to be energy dependent, but independent of calcium concentration or nerve stimulation.[18-20] Botulinum toxin does not affect the synthesis or storage of acetylcholine, but rather the release of vesicle-bound acetylcholine. The therapeutic effect is related to the peripheral blockade of neuromuscular activity through an enzyme-related interference in neurotransmitter exocytosis.[21,22]

There have been no long-term adverse effects of significant health hazard with the use of botulinum toxin type A for any indication.[22-25] Muscle biopsy specimens taken from patients after repetitive injections have failed to show any long-term evidence of permanent degeneration or atrophy and those patients have received dosages that were 2 to 5 times the dosages we have used for aesthetic improvement.[26,27] Patients receiving very high doses of toxin may also develop antibodies to the toxin; however, the antibodies are not dangerous, but render the patient unresponsive to further treatment. The factors that predispose patients to the development of antibodies is unknown, but some experience has shown that the risk is increased with the use of more than 300 U.[21,28] Therefore, we have developed and used an electromyography (EMG)–guided technique to increase the accuracy of the injection that may therefore minimize the dose and antigenic exposure.

Botulinum toxin type A has been approved by the Food and Drug Administration as safe and effective therapy for blepharospasm, strabismus, and hemifacial spasm since December 1989. The National Institutes of Health consensus conference of 1990 also included as safe and effective therapy the treatment of adductor spasmodic dysphonia, oromandibular dystonia, and cervical dystonia.[21]

PATIENTS

Our present series includes 210 different treatment sites in 162 patients. This includes 25 male patients and 137 female patients ranging in age from 21 to 78 years with a mean (±SD) age of 46.1 (±1.98) years (SEM, 0.07 years). All patients were given our internal review board–approved informed consent before treatment and inclusion in the study. The sites include 40 forehead, 89 glabella, 72 crow's feet, 4 platysma, 4 nasolabial, and 1 mentalis.

One international unit of botulinum toxin is defined as the median lethal dose in mice. The median lethal dose in humans is estimated to be approximately 3000 IU.[3] Lyophylized botulinum toxin type A (Botox, Allergan Inc, Irvine, Calif) was obtained and stored frozen as recommended (−20°C) until reconstitution with sterile saline at the time of injection.

INJECTION TECHNIQUE

In this study, the toxin was reconstituted with normal saline to a concentration of 25 to 50 U/mL. Botulinum toxin was injected via a monopolar hollow bore, Teflon-coated EMG needle connected to an EMG recorder. Using a technique we have previously described,[1,4,5,7-9,11,13,14] the needle is placed through the skin overlying the exaggerated facial line into the muscle associated with the hyperfunctional line. Once the needle is in the muscle, the patient is instructed to accentuate the line with a smile or frown, until the maximum EMG signal is achieved. The needle may be moved until it is in the most active part of the muscle complex. Toxin is then injected in 0.1-mL aliquots. By using an initial low dose, a graded weakening can be achieved over sequential visits.

PATIENT EVALUATION

Patients were first evaluated with a thorough review of their medical history, medications, and prior facial plastic surgery. Any patient who had a history of sensitivity to toxin, or had a neuromuscular disorder such as myasthenia or Eaton-Lambert syndrome, or those patients who could not complete the protocol were not treated. Preliminary photographs were taken for each patient and for each site both at rest and during activity. All photographs were standardized by using the same camera, lens system, flash system, and film. Photographs were obtained at 90 cm with a 105-mm lens oriented vertically using 400-slide film (EktaChrome, Kodax, Rochester, NY) and a 5-ring flash. A set of close-up photographs at 60 cm with the camera oriented horizontally was also obtained. Photographs were repeated at 2 weeks and 6 weeks after injection.

Patients and physicians independently rated the hyperfunctional lines with a 0- to 3-rating scale (0 reflecting no facial wrinkles; 1 signifying mild facial wrinkles; 2 denoting moderate facial wrinkles; and 3 representing severe facial wrinkling) at rest and during function, before injection, and at 2 and 6 weeks after injection. The physician and patient ratings were averaged and then tabulated and analyzed.

RESULTS

The doses used in this study were based on our previous experience and modified for some patients depending on response. The dose for forehead lines was 5 to 25 U with a mean (±SD) of 17.3±6.2 U (SEM, 1.0 U); glabellar lines, 5 to 20 U with a mean (±SD) of 11.1±3.1 U (SEM, 0.11 U); crow's feet, 5 to 15 U with a mean (±SD) of 6.2±1.6 U (SEM, 0.19 U); nasolabial, 2.5 to 5 U with a mean (±SD) of 3.12±1.2 U (SEM, 0.62 U); and platysma, 10 to 20 U with a mean (±SD) of 15±4 (SEM, 2 U). A beneficial response was found in 199 (95%) of 210 facial sites. All patients had toxin effect within the first 24 to 72 hours (**Table**).

Overall, the best average beneficial change in function was noted in the forehead (1.84, 46% improvement), followed by the glabellar area (1.5, 37.5% improvement) and crow's feet (1.36, 34% improvement). The rating

Dose and Response for Each Site*

Site	Average No. of Units	Δ Rating Rest	Δ Rating Action
Forehead	17.3	1.5 (37.8)	1.84 (46)
Glabella	11.1	1 (25)	1.5 (37.5)
Crow's feet	6.22	0.92 (23)	1.36 (34)
Platysma	15	0.75 (18)	1 (25)
Nasolabial	3.1	1 (25)	1.25 (31)

**Numbers within parentheses are percentage change before and after injection. The rating values are on the 0- to 3-point rating scale.*

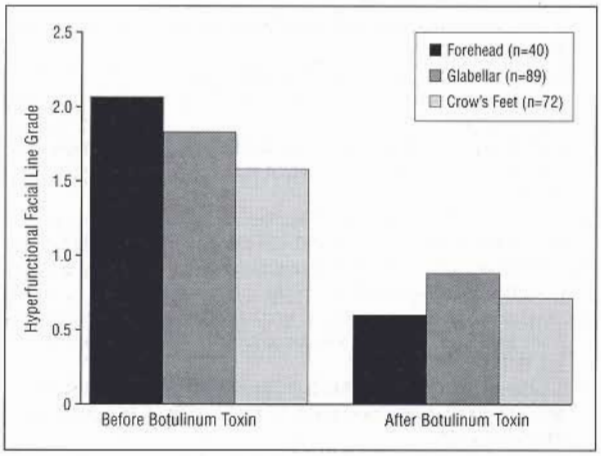

Figure 1. *Comparison of facial wrinkling based on the hyperfunctional facial line grading system: 0, no lines; 1, mild lines; 2, moderate lines; and 3, severe lines. We compare pre–botulinum toxin and post–botulinum toxin injection of hyperfunctional facial lines of the forehead, glabellar area, and crow's feet at rest. All areas treated had statistically significant reduction in the severity of the facial lines. For facial lines, N=201 regions. For conditions at rest, 1-tailed P<.001 for each.*

differences at rest were forehead, 1.45; glabella, 0.97; and crow's feet, 0.9. The *P* value for a 1-tail *t* test was .00005 (**Figure 1** and **Figure 2**). There were too few platysma and nasolabial injections to obtain statistically significant improvement data; however, an improvement trend was noted at these injection sites.

The adverse effects of the toxin injections were minimal and included 7 patients who experienced temporary droop of the eyelid or brow or droop of the upper lip (nasolabial fold injection). No systemic reactions were noted. The effects of the injection lasted on the average of 3 to 6 months, whereon most patients returned for reevaluation and treatment.

COMMENT

Hyperfunctional facial lines are common cosmetic deformities involving the forehead, glabellar area, nasolabial creases, and the lateral orbital region. These excessively prominent lines may be misinterpreted as anger, anxiety, fear, fatigue, and melancholia as well as aging.[13] Such lines have been treated with surgical excision, a procedure that often has minimal effect on the lines and leaves unslightly scars. Other options include collagen, silicone, or fat injection in an effort to balloon out the skin and flatten the folds.[13,29-31]

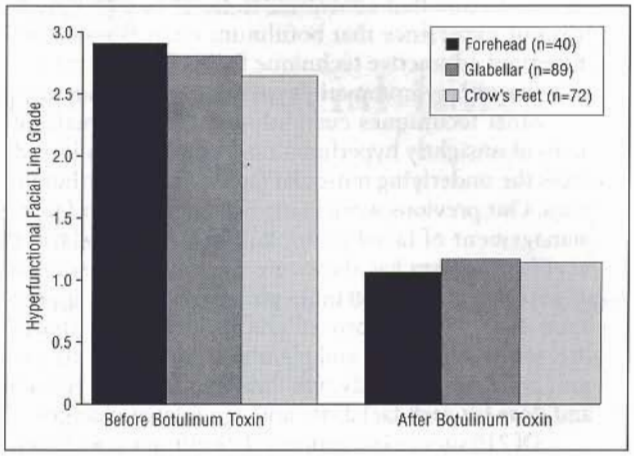

Figure 2. *Comparison of facial wrinkling based on the hyperfunctional facial line grading system (see legend to Figure 1 for explanation). We compare pre–botulinum toxin and post–botulinum toxin injection of hyperfunctional facial lines of the forehead, glabellar area, and crow's feet during function. All areas treated had statistically significant reduction in the severity of the facial lines that is even more apparent during function. For facial lines, N=201 regions. For conditions with action, 1-tailed P<.001 for each.*

Most facial rejuvenation procedures do not address the cause of the hyperfunctional lines. These lines appear to be the result of a functional pull of the underlying mimetic facial musculature. Patients who have Bell palsy have been observed to have smooth skin without deep hyperfunctional lines. Botulinum toxin weakens the overactive underlying muscle contraction, causing a flattening of the facial skin and an improved cosmetic appearance.[1,13,17,23-25,32]

Other facial lines related to actinic skin changes or age-related loss of dermal elasticity with a laxity of facial skin may not respond to the toxin. In very young patients, subtle changes at rest are harder to appreciate, such as the effect on the medial forehead.

Botulinum toxin has several advantages over other techniques of management of hyperfunctional facial lines. Botox can be performed during a routine office visit, with minimal discomfort. The injections may be given serially with small doses to titrate the results while a patient's treatment strategy is being formulated. The only morbidity was related to temporary mild weakness of other adjacent facial muscles. The EMG technique allows for accurate placement of the needle electrode in the more active portions of the muscle, which may achieve maximum effect with minimum dose. Accurate EMG placement and minimal dose is likely responsible for a low incidence of morbidity of our technique and the overwhelmingly successful effects of the injections. Overall, the best average change in function was noted in the forehead, followed by the glabellar area and then in crow's feet. More than 80% of the patients were extremely pleased with the results and returned for further treatment at 4 to 5 months when the effect wore off.

Continued work is necessary to determine the exact mechanism of the toxin, the short-term and long-term effects on muscle, and adjuvants or other mechanisms to obtain longer periods of benefit. Botulinum toxin may also provide a useful laboratory tool to explore the

various factors that contribute to facial line formation. It is our experience that botulinum toxin is a safe and important adjunctive technique for the management of patients with symptomatic hyperfunctional facial lines.

Most techniques currently used for the management of unsightly hyperfunctional facial lines fail to address the underlying muscular factors that contribute to lines. Our previous work using botulinum toxin for the management of facial dystonia, facial synkinesis, and hemifacial spasm has shown a reduction in the severity of the facial lines and a more pleasing cosmetic appearance. We previously proved efficacy in another study[14] that was double-blind and placebo controlled. This current collaborative study was designed to study efficacy and dose for each facial site and age-related changes.

Of 210 sites in 162 patients, 95% efficacy was shown. Qualitative measurements were made using a 0- to 3-point severity scale index before injection and after injection. Patients had only 1 site injected in any given period. The injections were EMG guided to minimize dose, improve the precision of the delivery, and maximize effect. The best results were found in the management of forehead lines, followed by glabellar and crow's feet. Benefits were also seen with nasolabial lines and platysmal bands. There was also a trend in the need for increased dose with increased age. The effects of the toxin were seen within 24 to 72 hours and lasted on average 4 to 6 months.

Additional studies will be necessary to determine the exact mechanism of the toxin, the short-term and long-term effects on muscle, and adjuvants or other mechanisms to obtain longer periods of benefit. Botulinum toxin is a safe and important adjunctive technique for the treatment of patients with symptomatic hyperfunctional facial lines.

Accepted for publication January 14, 1997.

Presented at the American Academy of Facial Plastic and Reconstructive Surgery Meeting, Minneapolis, Minn, September 30, 1993.

Reprints: Andrew Blitzer, MD, DDS, 425 W 59th St, New York, NY 10019 (e-mail: AB1136@aol.com).

REFERENCES

1. Brin MF, Fahn S, Moskowitz C, et al. Localized injections of botulinum toxin for the treatment of focal dystonia and hemifacial spasm. *Mov Disord.* 1987; 2:237-254.
2. Kang U, Greene P, Fahn S, et al. Double-blind placebo-controlled study of botulinum toxin injection for torticollis. *Neurology.* 1988;38:244.
3. Brin MF, Fahn S, Moskowitz CB, Blitzer A, Friedman A, Shale HM. Injections of botulinum toxin for the treatment of focal dystonia. *Neurology.* 1986;36(suppl 1):176.
4. Brin MF, Fahn S, Moskowitz CB, et al. Localized injections of botulinum toxin for the treatment of focal dystonia and hemifacial spasm. *Mov Disord.* 1987; 2:237-254.
5. Blitzer A, Brin M, Fahn S, Lovelace RE. The use of botulinum toxin in the treatment of focal laryngeal dystonia (spastic dysphonia). *Laryngoscope.* 1988;98: 193-197.
6. Blitzer A, Brin MF, Fahn S. Botulinum toxin injection for the treatment of oromandibular dystonia. *Ann Otol Rhinol Laryngol.* 1989;98:93-97.
7. Brin MF, Blitzer A, Fahn S, Lovelace RE. Adductor laryngeal dystonia: treatment with local injections of botulinum toxin (Botox). *Mov Disord.* 1988;4: 287-296.
8. Brin MF, Blitzer A, Fahn S, et al. Adductor laryngeal dystonia (spastic dysphonia): treatment with local injections of botulinum toxin (Botox). *Mov Disord.* 1989;4:287-296.
9. Blitzer A, Brin MF. Laryngeal dystonia: a series with botulinum toxin therapy. *Ann Otol Rhinol Laryngol.* 1991;100:85-90.
10. Blitzer A, Brin MF, Fahn S. Botulinum toxin injection for the treatment of oromandibular dystonia. *Ann Otol Rhinol Laryngol.* 1989;98:93-97.
11. Blitzer A, Brin MF, Stewart C, Fahn S. Abductor laryngeal dystonia: a series treated with botulinum toxin. *Laryngoscope.* 1992;102:163-167.
12. Blitzer A, Brin MF, Fahn S. Botulinum toxin injections for lingual dystonia. *Laryngoscope.* 1991;101:799.
13. Blitzer A, Brin MF, Keen MS, Aviv JS. Botulinum toxin for the treatment of hyperfunctional lines of the face. *Arch Otolaryngol Head Neck Surg.* 1993;119: 1018-1023.
14. Keen MS, Blitzer A, Aviv JE, et al. Botulinum toxin A for hyperkinetic facial lines: results of a double blind placebo controlled study. *Plast Reconstr Surg.* 1994;94:94-99.
15. Keen M, Kopelman JE, Aviv JE, Binder W, Brin MF, Blitzer A. Botulinum toxin A: a novel method to remove periorbital wrinkles. *Facial Plast Surg.* 1994;10: 141-146.
16. Carruthers A, Carruthers J. Aesthetic indications for botulinum toxin injections. *Plast Reconstr Surg.* 1995;95:427-428.
17. Simpson LL. The origin, structure, and pharmacological activity of botulinum toxin. *Pharmacol Rev.* 1981;33:155-188.
18. Simpson LL. Kinetic studies on the interaction between botulinum toxin type A and the cholinergic neuromuscular junction. *J Pharmacol Exp Ther.* 1980; 212:16-21.
19. Simpson LL, Dasgupta BR. Botulinum neurotoxin type E: studies on mechanism of action and on structure activity relationships. *J Pharmacol Exp Ther.* 1983;224:135-140.
20. Black JD, Dolly JO. Interaction of ^{125}I-labelled botulinum neurotoxins with nerve terminals, I: ultrastructural autoradiographic localization and quantitation of distinct membrane acceptors for types A and B on motor nerves. *J Cell Biol.* 1986;103:521-534.
21. National Institutes of Health Consensus Development Conference. *Clinical Use of Botulinum Toxin.* Bethesda, Md: National Institutes of Health; 1990; 8:1-20.
22. Hambleton P, Moore AP. Botulinum neurotoxins: origin, structure, molecular actions, and antibody. In: Moore P, ed. *Handbook of Botulinum Toxin Treatment.* Boston, Mass: Blackwell Scientific Publications Inc; 1995:16-27.
23. Tosoy EA, Bukley EG. Treatment of blepharospasm with botulinum toxin. *Am J Ophthalmol.* 1985;99:176.
24. Scott AB, Kennedy RA, Stubbs HA. Botulinum toxin A injection is a treatment for blepharospasm. *Arch Ophthalmol.* 1984;103:347.
25. Maoriello JA Jr. Blepharospasm Meige's syndrome and hemifacial spasm: treatment with botulinum toxin. *Neurology.* 1985;35:1499.
26. Borodic GE, Ferranter R. Effects of repeated botulinum toxin injections on orbicularis oculi muscle. *J Clin Neuro-Ophthalmol.* 1992;12:121-127.
27. Scott AB, Kennedy RA, Stubbs HA. Botulinum toxin injection as a treatment for blepharospasm. *Arch Ophthalmol.* 1985;103:347-350.
28. Borodic G, Johnson E, Goodnough M, Schantz E. Botulinum toxin therapy, immunologic resistance, and problems with available materials. *Neurology.* 1996; 46:26-29.
29. Newmark S, Dolsky R, Nguyen A. Facial profile plasty by liposuction extraction. *Otolaryngol Head Neck Surg.* 1988;98:718-731.
30. Pitanguy I. Indications for treatment of frontal and glabellar wrinkles in an analysis of 3,404 consecutive cases of rhytidectomy. *Plast Reconstr Surg.* 1981; 67:157-166.
31. Pollack SV. Silicone, fibrel, and collagen implantation for facial lines and wrinkles. *J Dermatol Surg Oncol.* 1990;16:957-961.
32. Lange DH, Rubin M, Greene PE, et al. Distant effects of locally injected botulinum toxin: a double-blind study of single fiber EMG changes. *Muscle Nerve.* 1991;14:672-675.

Printed and Published in the United States of America