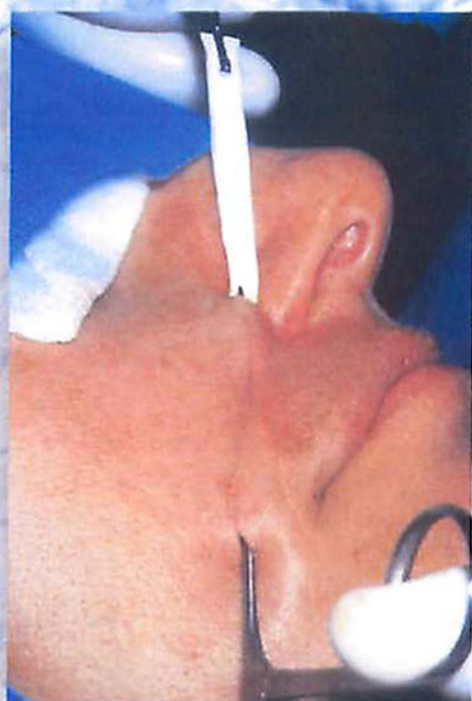


MANAGEMENT OF FACIAL LINES AND WRINKLES



EDITORS

**ANDREW BLITZER
WILLIAM J. BINDER
J. BRIAN BOYD
ALASTAIR CARRUTHERS**



LIPPINCOTT WILLIAMS & WILKINS

CHAPTER 8

FACIAL CONTOURING: THE EFFECTIVE USE OF FACIAL IMPLANTS

Facial Contouring and Facial Implants

- ▶ *Pathophysiologic Considerations of Aging*
- ▶ *Preoperative Analysis* ▶ *Procedure*
- ▶ *Complications* ▶ *Conclusion*

William J. Binder

The role of augmentation procedures has expanded the use of facial implants from increasing skeletal dimension to augmentation of soft tissue for the purpose of facial rejuvenation and the reduction of facial rhytids. The challenge today is a customized approach to problems in contour restoration, which must include patient evaluation, defined clinical indications, and precise selection of implant material and shape. Reliance on soft-tissue procedures alone, such as rhytidectomy, collagen, or botulinum toxin, will correct only specific causes of skin wrinkling. However, skin redundancy and wrinkling caused by insufficient skeletal structure or the absence of soft-tissue volume requires treatment with specific facial contouring procedures. This chapter focuses on the appropriate use of facial aug-

W.J. Binder: Department of Head and Neck Surgery, UCLA School of Medicine; and Department of Otolaryngology and Head and Neck Surgery, Cedars Sinai Medical Center, Los Angeles, California 90069.

mentation to provide balanced aesthetic contours and help reduce some of the characteristics of aging to provide a more youthful appearance.

► Facial Contouring and Facial Implants


Facial Implants and Biomaterials

The use of biomaterials requires a knowledge of host response and an understanding of potential adverse reactions to given materials. The ideal implant material is cost-effective, nontoxic, nonantigenic, and noncarcinogenic. The material should be inert, easily shaped, able to maintain desired form, and be permanently accepted. There must be host acceptability with high resistance to infection. Biocompatibility is also influenced by the physical properties of the implant such as firmness and its surface characteristics.

Surgical technique, size of the device, and preparation also play roles in the success of the implant procedure. Ideally, the implant's posterior configuration should conform to the bony surface of the facial skeleton. The anterior surface shape should emulate the desired natural facial configuration. The implants should be readily implantable, and the margins must be tapered to blend onto the bony surface so that they will be nonpalpable. They should be malleable, conformable, and readily exchangeable. Permanent fixation or fibrous encapsulation to immobilize them from the surrounding tissues are often undesirable, particularly if the patient desires to change augmentation characteristics in later years. The natural encapsulation process of silicone elastomer ensures immobility yet provides exchangeability without damage to surrounding soft tissue. I now use a new form of silicone rubber implant, the Conform type of implant (Conform is a trademark of Implants Associates, Inc., Ventura, CA, U.S.A.). This implant has a new type of grid backing that reduces the memory of the silicone rubber and also incorporates improvements of shape, flexibility and softness (Fig. 8-1).

Figure 8-1

The Conform type of implant depicted here is made from a softer silicone material and has a grid design on the back surface of the implant, which reduces its memory so that it more easily conforms to the underlying bony surface. The grid feature reduces the chances of implant slippage and displacement, and the softer material has a more natural feel to the implanted prosthesis (Patent no: 5,876,447).



Facial Contouring

Facial contouring means changing the shape of the face. Modern hallmarks of beauty are distinguished by bold facial contours that are accentuated by youthful malar-midface configurations and a sharp, well-defined jawline. Despite the most radical or extensive deep-plane or submuscular aponeurotic system (SMAS) techniques, a face-lift is unable to accomplish significant change in facial contour. Only judicious alterations of mass and volume will produce these desired changes. Technically, this is accomplished by selecting implants with the proper shape and controlling their position on the facial skeleton.

► Pathophysiologic Considerations of Aging

Involitional soft-tissue changes brought on by age, weight loss, or even excessive exercise may bring about facial flaws that appear progressively more obvious and pronounced with age. It is generally acknowledged that patients endowed with strong, well-balanced skeletal features will best endure the ravages of age (1). Analysis of the faces of teenagers reveals an abundance of soft tissues providing a homogeneous composite of facial form. Full cheeks and smooth, harmonious, and symmetric contours free of sharp, irregular projections, indentations, or skin wrinkling commonly embody these youthful qualities (2).

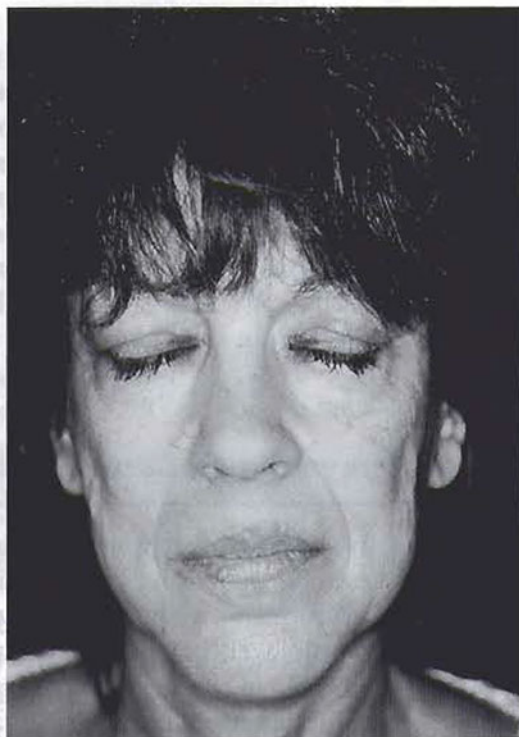Recognizing these various defects and configurations caused by aging is an integral part of the subject of facial contouring. During the aging process, depending on the underlying skeletal structure, different but definable configurations of the face are formed, with distinctive changes brought about by the disproportionate draping of the skin. This depends to a large degree on the amount of underlying fatty tissue and skin type. These configurations may include the development of a generalized flattening of the midface, thinning of the vermilion border of the lips, the formation of jowls, areas of deep cavitory depressions of the cheek, and the formation of deep wrinkling or folds of the skin (3). Other specific soft-tissue configurations include the prominence of the nasolabial folds, flattening of the soft-tissue button of the chin, and formation of the prejowl sulcus in part by the relaxation of the soft tissue forming the jowl and surrounding an area of bone resorption along the body of the mandible (4,5) (Fig. 8-2).

In the midface, most soft-tissue deficiencies are found within the recess described as the submalar triangle (6). This inverted triangular area of midfacial depression is bordered above by the prominence of the zygoma, medially by the nasolabial fold, and laterally by the body of the masseter muscle (Fig. 8-3A and B). In cases of severe degenerative changes of the skin and loss or lack of underlying soft tissue and fat, which if combined with deficient underlying bone structure is an exaggeration of the gravitational effects of aging, folds and wrinkles become deeper than one would normally expect. These conditions often preclude rhytidectomy alone from rejuvenating the face completely.

Among many techniques evolving in facial rejuvenation surgery, the missing link still remains the ability to permanently replace soft-tissue bulk in sufficient quantity. Therefore if it is not present and cannot be replaced or repositioned, then

Figure 8-2

Resorption of bone within the anterior mandibular groove, coupled with progressive encroachment of the jowl, creates the prejowl sulcus and contributes to the development of the marionette lines. In these conditions, the prejowl implant is used to augment and help correct this specific deficiency and assist the rhytidectomy to achieve the desired straight mandibular line and prevent recurrence of the jowl. (From ref. 11, with permission.)



it will require either actual or a simulated replacement. This problem must be addressed by supplemental techniques that have the ability to soften sharp angles or depressions, smooth out wrinkles, and augment inadequate skeletal structure (7-9).

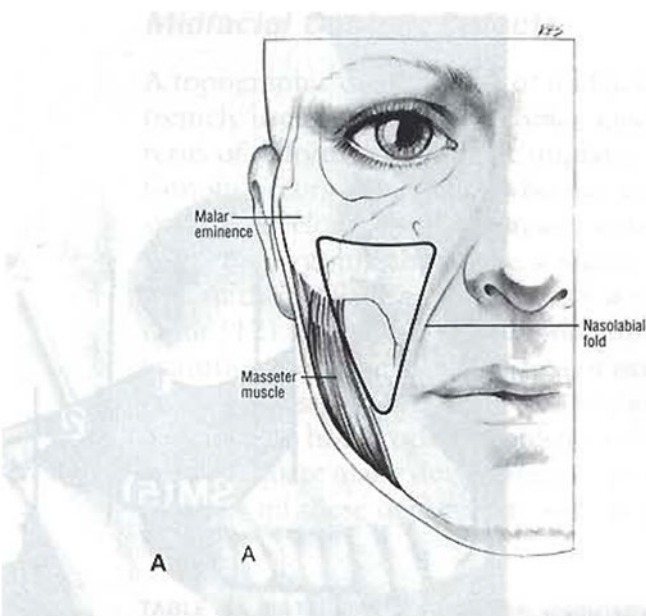
Acknowledging these elements of structural deficiency and phenomena of aging, we may elect to use a new generation of computer-aided design/computer-aided manufacture (CAD/CAM) polymeric silicone Silastic (Dow Corning) facial implants that have the necessary refinements and greater anatomic accuracy for improved results in facial contour (10). Along with rhytidectomy, laser resurfacing, and the many other adjunctive techniques, facial implants are used collectively to reduce wrinkling of the skin and to restore and prolong the optimal aesthetic qualities of the youthful face.

► Preoperative Analysis

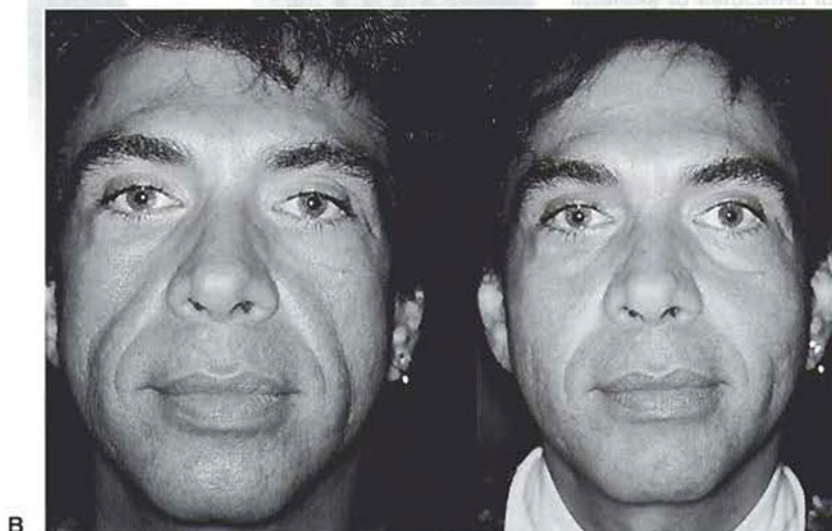
Correct analysis and identification of distinctive and recognizable configurations of facial deficiency are essential for choosing the optimal implant shape and size to obtain the best results in facial contouring.

Mandibular Contour Defects

Delineation of zonal principles of anatomy within the premandible space allows the surgeon to create specific chin and jawline contours. Over the past 30 years, traditional chin implants have essentially been placed over the area between the

**Figure 8-3**

A: The inverted submalar triangle is an area of midfacial depression bordered medially by the nasolabial fold, superiorly by the malar eminence, and laterally by the main body of the masseter muscle. **B:** Left, preoperative: Significant depth to the submalar triangular recess is shown in this patient, who had already undergone face-lift surgery 1.5 years before photograph was taken. Without providing supplementary support for the lack of midfacial soft tissue, the deep facial recess, along with the adjacent prominent nasolabial fold, spontaneously returned 3 months after the initial face-lift surgery. Right, 6 months after surgery: Submalar augmentation was used as the sole procedure to reexpand the midfacial depression. By augmenting this depressed midfacial area, the prominence of the adjacent nasolabial fold is simultaneously reduced. (From ref. 11, with permission.)



mental foramina. This familiar location constitutes only one segment or zone of the mandible that can be successfully altered. Implants placed in the central segment alone and without extension often produce abnormal round protuberances that are unattractive (Fig. 8-4). A midlateral zone within the premandibular space can be defined as the region extending from the mental foramen posteriorly to the oblique line of the horizontal body of the mandible. When this zone is augmented in addition to the central mentum, a widening of the anterior jawline contour results. This is the basis for the development of the extended anatomic and prejowl chin implant (Fig. 8-5A and B). The posterior lateral zone is a third zone of the premandibular space, which encompasses the posterior half of the horizontal body including the angle of the mandible and the first 2 to 4 cm of the ascending ramus. This zone can be modified with a mandibular-angle implant, which will either widen and/or elongate the posterior mandibular angle to produce a strong posterior jawline contour.

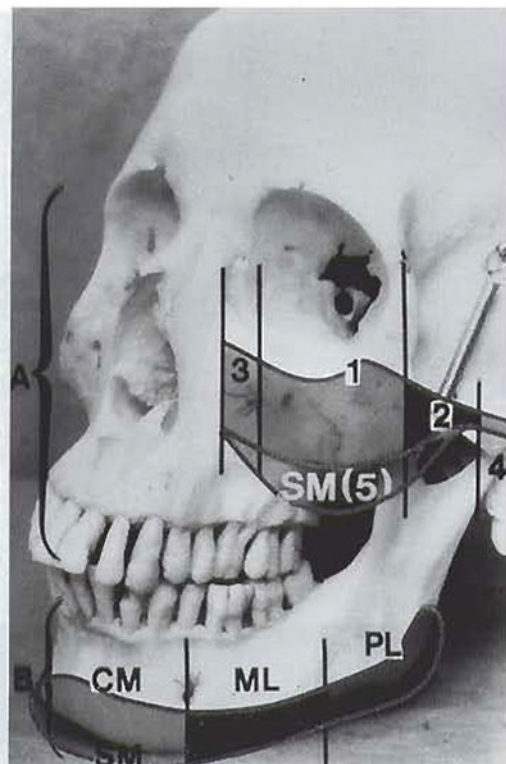


Figure 8-4

Alloplastic facial contouring by zonal principles of skeletal anatomy. The three zones of mandibular augmentation: central mentum (CM), midlateral (ML), and posterolateral (PL). (From Binder WJ, et al. Augmentation of the malar-submalar/midface. *Facial Plast Surg Clin North Am* 1994;2:265-283.)

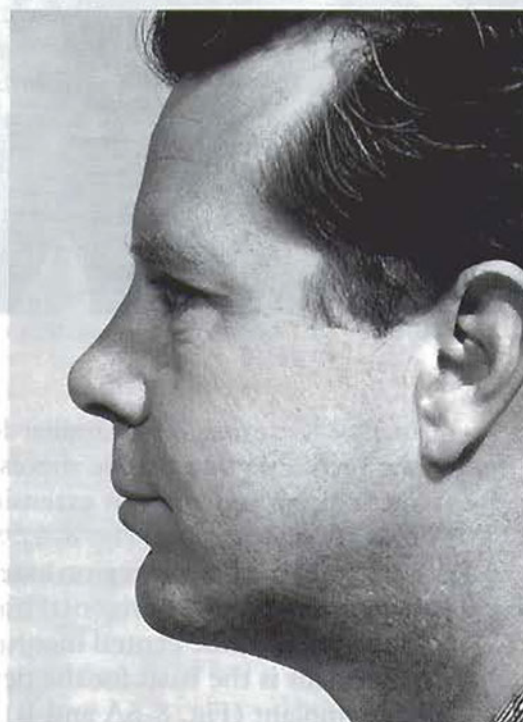
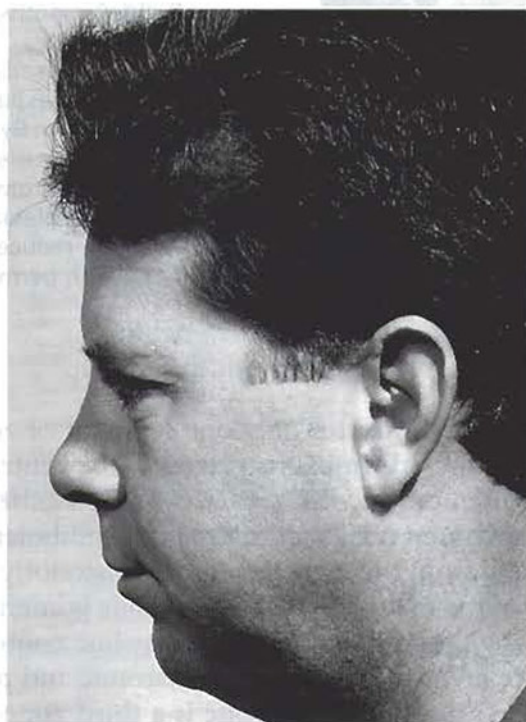
Figure 8-5

A: Before surgery. **B:** After surgery. Example of using an extended mandibular implant in addition to liposuction to create a significantly improved jawline and neckline.

Midfacial Contour Defects

A topographic classification of midfacial contour deficiencies has proven to be extremely useful as a basic reference guideline to correlate distinctive anatomic patterns of deformity to specific implants (11) (Table 8-1; Fig. 8-6A-E). Type I deformity occurs in a patient who has good midfacial fullness but insufficient malar skeletal development. In this case, a malar shell implant would be desirable to augment the zygoma and create a higher arch to the cheekbone. The larger surface area of the implant imparts greater stability and helps reduce rotation or displacement (12). Inferior extension into the submalar space establishes a more natural transition from the localized area of maximal augmentation to contiguous areas of relative recession (Fig. 8-7). The second type of deformity (type II), occurs in the patient who has atrophy or ptosis of the midfacial soft tissues in the submalar area with adequate malar development. In this case, submalar implants are used to augment or fill these depressions and/or provide anterior projection (Fig. 8-8A and

TABLE 8-1. PATTERNS OF MIDFACIAL DEFORMITIES CORRELATED WITH TYPE OF IMPLANT

Deformity Type	Description of Midfacial Deformity	Type of Augmentation Required	Type of Implant Predominantly Used
Type I	Primary malar hypoplasia; adequate submalar soft tissue development	Requires projection over the malar eminence.	Malar Implant: "shell-type" implant extends inferiorly into submalar space for more natural result.
Type II	Submalar deficiency; adequate malar development	Requires anterior projection. Implant placed over face of maxilla and/or masseter tendon in submalar space. Also provides for midfacial fill.	Submalar Implant (Generation I)
Type III	Extreme malar-zygomatic prominence; thin skin; with abrupt transition to a severe submalar recess	Requires normal anatomic transition between malar and submalar regions; plus moderate augmentation around inferior aspect of zygoma.	Submalar Implant (Generation II): more refined; "U"-shaped to fit w/in submalar space & around inferior border of prominent zygoma.
Type IV	Both malar hypoplasia and submalar deficiency	Requires anterior and lateral projection; "volume replacement implant" for entire midface restructuring.	"Combined" Submalar-Shell Implant; lateral (malar) & anterior (submalar) projection. Fills large midfacial void.
Type V	Tear-trough deformity (Infraorbital rim depression or recess)	Requires site-specific augmentation along infraorbital rim.	"Tear-trough Implant"; to fit site-specific suborbital groove.

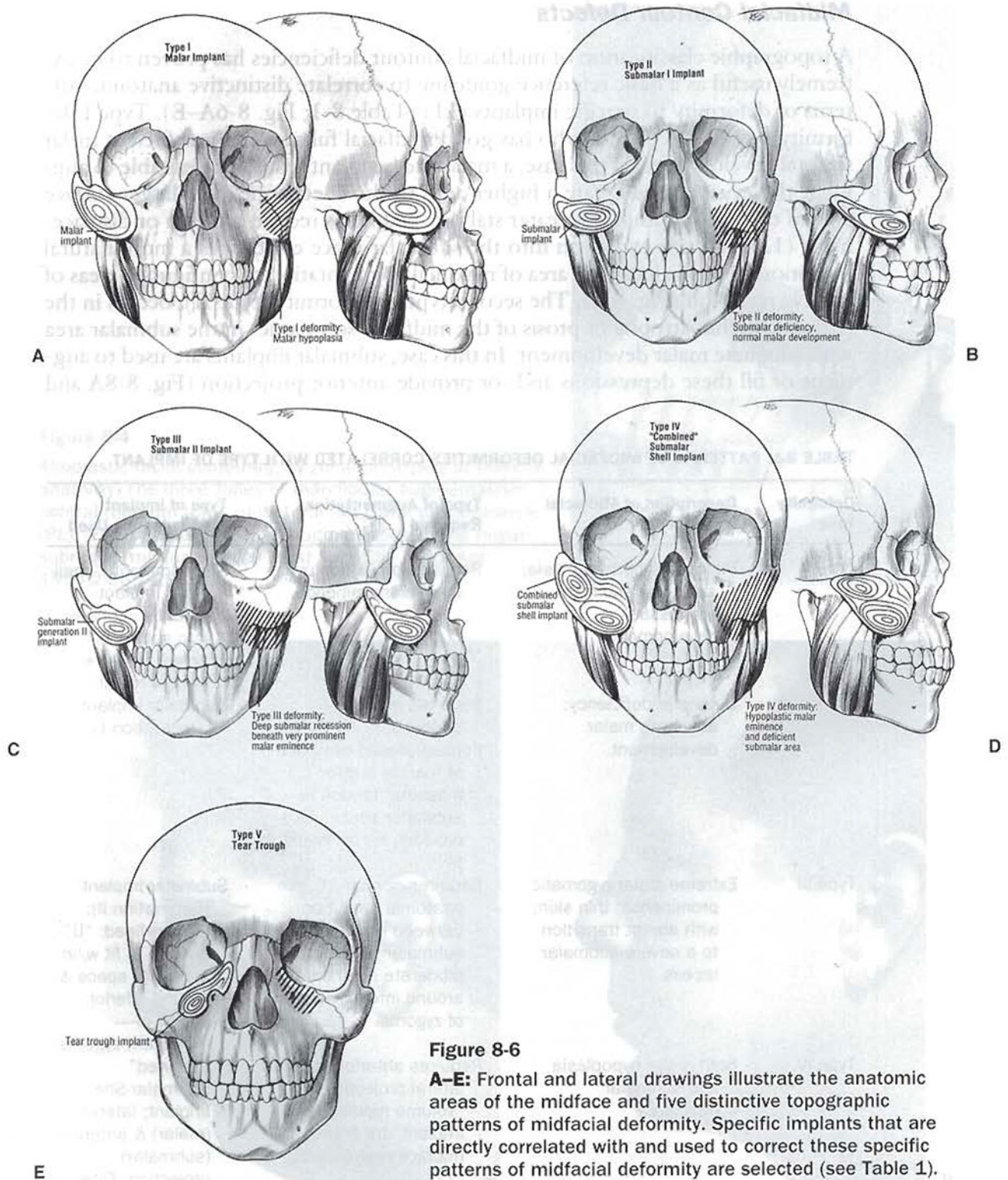
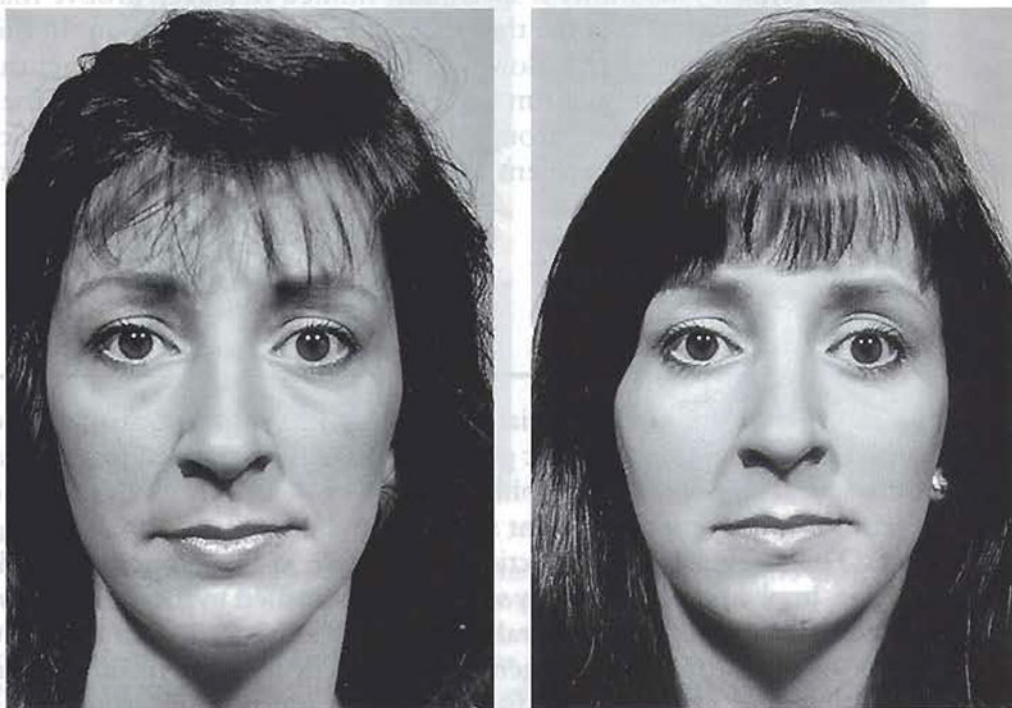

Figure 8-7

Left: Before surgery. Example of malar hypoplasia (type I deficiency). Right: Eight months after malarplasty with a Malar-Shell implant. Augmentation of a greater surface area extension inferiorly into the submalar space produces a more natural high-cheekbone effect.

**Figure 8-8**

A: Before surgery, this patient has a relatively good malar bone structure but was complaining of early flatness to the midface (type II deformity). **B:** Submalar augmentation restored the anterior projection to the middle third of the face, providing a more youthful expression, as well as reducing the depth of the nasolabial folds.

B). Type III deformity occurs in a patient who has thin skin and exceptionally prominent malar eminences. These characteristics combine to cause an abrupt transition from the cheekbone superiorly to an extreme area of hollowness found within the submalar region, producing an exceptionally gaunt or skeletonized facial appearance. In this group of patients, a second-generation submalar transition implant is used to fill the abrupt midfacial hollow. Type IV deformity is the result of malar hypoplasia and submalar soft-tissue deficiency, which is described as the "volume-deficient" face. In this situation, a single combined malar-submalar implant must serve two purposes: it must proportionately augment a deficient skeletal structure over the malar area and fill the void created by absent midfacial soft tissue within the submalar area. Because this condition is also associated with premature aging of the skin with excessive midfacial wrinkling and deep folds, these patients are often classified as suboptimal candidates for rhytidectomy. As seen in Fig. 8-9A-D, total midfacial restoration and lateral mandibular augmentation, by using a combined malar-submalar implant and prejowl implant, provide the structural basis for this patient to derive greater benefit from the concurrently performed rhytidectomy procedure and successfully eliminate the deep folds that were present in the medial middle third of the face. The "tear-trough (type V) deformity is specifically limited to a deep groove that commonly occurs at the junction of the thin eyelid and thicker cheek skin. In this deformity, a pronounced fold extends downward and laterally from the inner canthus of the eye across the infraorbital rim and the suborbital component of the malar bone (13). Flowers used a tear-trough silicone elastomer implant, and Schoenrock, a Gore-Tex implant to augment this region, whereas others used autogenous fat grafts (14).

► Procedure

Considering the infinite variations of facial form, most analytic measurements used in determining aesthetic guidelines have been unreliable. Being able to identify specific types of topographic anatomy or deformity guides the surgeon in determining the optimal implant selection and placement.

The safest level of dissection in the face is the subperiosteal plane. In this plane, implants become firmly secured and attached to the skeleton by fibrosis and are usually stable within several days. Dissection is facilitated by adequate infiltration of diluted anesthetic agents. A sufficient amount of infiltration minimizes bleeding and facilitates the dissection. The addition of hyaluronidase (Wydase) disperses the local anesthetic agent and reduces soft-tissue distortion. The dissected compartments should be larger than the implant to accommodate it comfortably.

The day before surgery, the patient is started on a broad-spectrum antibiotic regimen, which continues for 5 days after surgery. Intravenous antibiotics and dexamethasone also are administered perioperatively. Before starting anesthesia, and while the patient is in an upright position, the precise area to be augmented is outlined with a marking pen. The initial outline that is drawn on the skin assists both the surgeon and patient to decide on the most appropriate shape, size, and




Figure 8-9

A: Frontal. **B:** Oblique. **C:** Head down. **D:** Lateral. **A–D**, left: Preoperative analysis of the facial configuration in this 40-year-old patient reveals the presence of severe deficiency in both skeletal structure and soft-tissue volume, contributing primarily to the excessive wrinkling of the skin in the area of the midface. **A–D**, right: 7 months after surgery, performed concurrent with rhytidectomy. The combined submalar-shell implants were used to restructure the entire midface, and a prejowl implant was used to add width to the mandible. In this patient, these augmentation procedures were essential for the structural and volumetric enhancement required for the face-lift procedure to provide a meaningful, long-term improvement. (From ref. 11, with permission.) (continued)

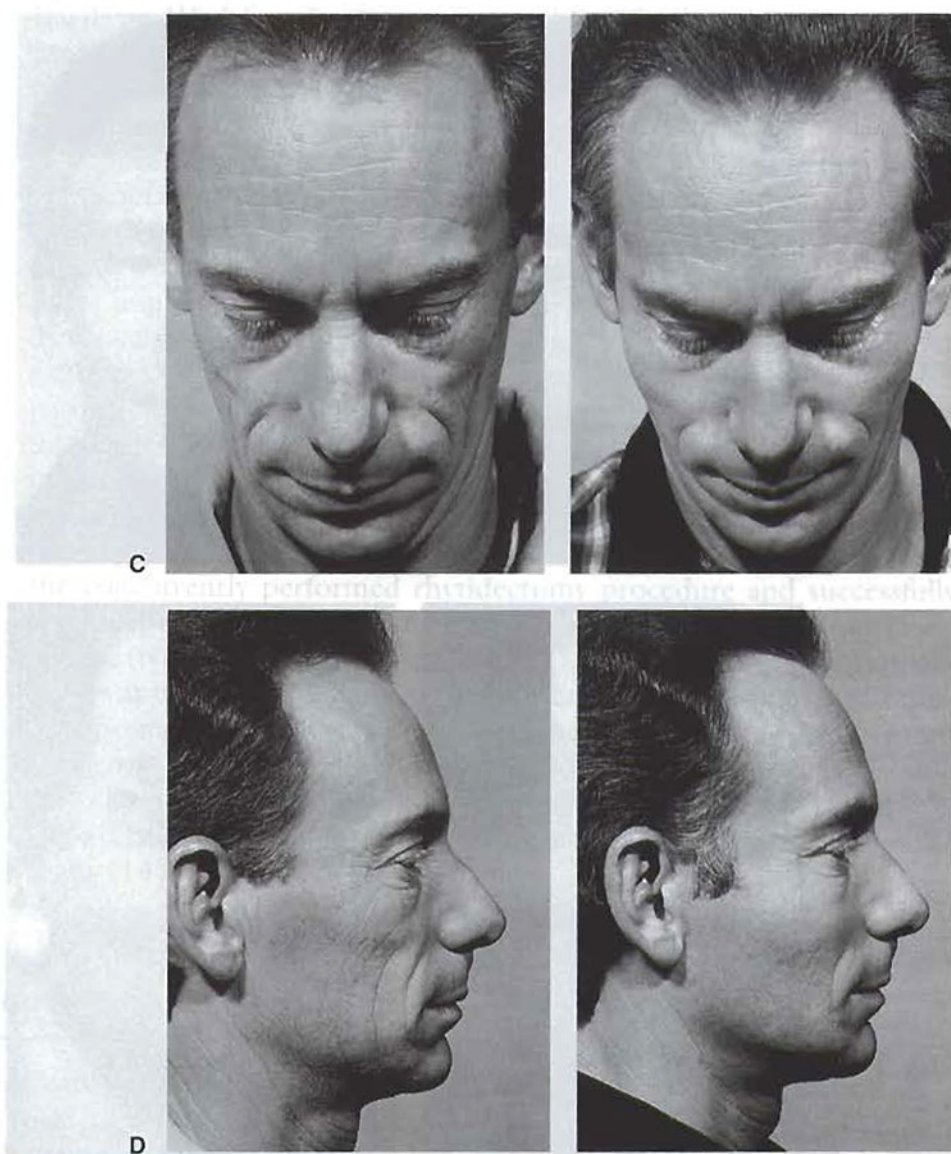


Figure 8-9 (Continued)

implant position to optimize their mutual goals (Fig. 8-10). Accurate identification of the type of facial deficiency becomes extremely helpful in trying to assess implant selection.

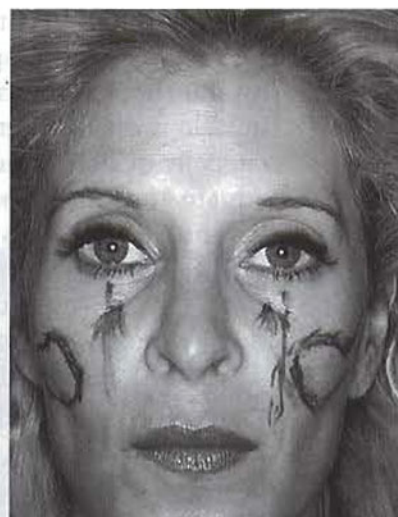The basic surgical principles for dissection augmenting the malar, midfacial, and premandibular spaces are identical, whereas controlling the shape, size, and positioning of the implant will determine the overall final facial contour.

Surgical Technique for Mandibular Augmentation

Basic technical rules should be followed for safe and accurate mandibular augmentation.

Figure 8-10

Before infiltration of local anesthetic, the areas requiring augmentation are specifically outlined, with the patient sitting in the upright position. In the majority of cases, the medial border of submalar or malar implants is placed lateral to the infraorbital foramen, corresponding approximately to the midpupillary line. (From ref. 11, with permission.)



1. Stay on bone. Placement of implants in the subperiosteal plane creates a firm and secure attachment of the implant to the bony skeleton. Strong adherence of periosteum along the inferior border of the mandible composes the origins of the anterior mandibular ligament, which defines the prejowl sulcus at the inferior aspect of the aging marionette crease. Often these ligamentous attachments must be incised to allow dissection to continue along the inferior segment of the mandible.
2. Dissection of this space must be adequately expanded to accommodate the prosthesis comfortably. A sharp dissecting instrument may be used on the central bone, but only blunt instruments are used around the nerves and adjacent to soft tissues.
3. The mental nerve should be avoided. This is accomplished by compressing the tissues around the mental foramen with the opposite hand. This helps to direct the elevator away from the nerve and along the inferior border of the mandible. The upward course of the mental nerve helps to protect it from trauma when dissection is from below. Temporary hypesthesia of the mental nerve can occur for several days to several weeks after surgery. Permanent nerve damage is extremely rare and represents less than half of 1% of a statistically large numbers of cases (15).
4. A dry operative field is essential for accurate visualization, precise dissection, proper implant placement, and the prevention of postoperative hematoma or seroma.

Choice of Incisions

Access to the premandibular space can be accomplished by either an intraoral or external route. The external route uses a 1- to 1.5-cm incision that immediately accesses the inferior border of the mandible. Advantages of the external route are that it does not involve intraoral bacterial contamination, it has direct access to the inferior mandibular border where cortical bone is present, it does not require significant retraction of the mental nerves, and it allows the implant to be secured to the periosteum along the inferior mandibular border with simple suture fixation.

This helps to prevent side-to-side or vertical slippage. The intraoral route provides the obvious advantage of leaving no external scars. The entry wound for the intraoral route is a transverse incision made through the mucosa. Then the mentalis muscle is divided vertically in the midline raphe to avoid transection of the muscle belly or detachment from the bony origins. This midline incision provides adequate access inferiorly to the bone of the central mentum and eliminates potential muscle weakness that may occur if the muscle is transected.

A Joseph's or 4-mm periosteal elevator is used to perform the dissection along the inferior mandibular border. Once the pockets are large enough, one side of the silicone rubber implant is inserted into the lateral portion of the pocket on one side and then folded upon itself to allow insertion of the contralateral portion of the implant. The implant is then adjusted into position.

Mandibular-Angle Implants

Access to the angle of the mandible is achieved through a 2-cm mucosal incision at the retromolar trigone. Dissection is performed on bone and beneath the masseter muscle to elevate the periosteum upward along the ascending ramus and then anteriorly along the body of the mandible. A curved (>90 degree) dissector is used to elevate the periosteum around the posterior aspects of the angle and ramus of the mandible. This permits accurate placement of the angle implants that are specifically designed to fit the posterior bony border of the ascending ramus and enhance mandibular angle definition. These implants are secured with a titanium screw.

Choosing Premandibular Implants

Implants expanding into the midlateral or parasymphysal zone produce anterior widening of the lower third of the facial segment. The average central projection required lies between 6 and 9 mm for men and 4 and 7 mm for women. Occasionally in a patient with severe microgenia, implants measuring ≥ 12 mm in projection may be necessary to create a normal profile and a broader jawline.

Surgical Techniques for Malar and Midface Contouring

The primary route for entering the malar-midfacial areas is the intraoral approach. Other approaches include the subciliary (via lower blepharoplasty), transconjunctival, rhytidectomy, zygomaticotemporal, and transcoronal routes.

Intraoral Route

The intraoral route is the most common and the preferred route for most midfacial implants with the exception of the tear-trough implant. After infiltration of the anesthetic solution, a 1-cm incision is made through the mucosa and carried directly down to bone in a vertical oblique direction above the buccal-gingival line and over the lateral buttress (Fig. 8-11A). Because the mucosa will stretch and allow complete visual inspection of the midfacial structures, a long incision through adjacent submucosal or muscular layers is not necessary and is discouraged. The incision should be made high enough to leave a minimum of 1 cm of

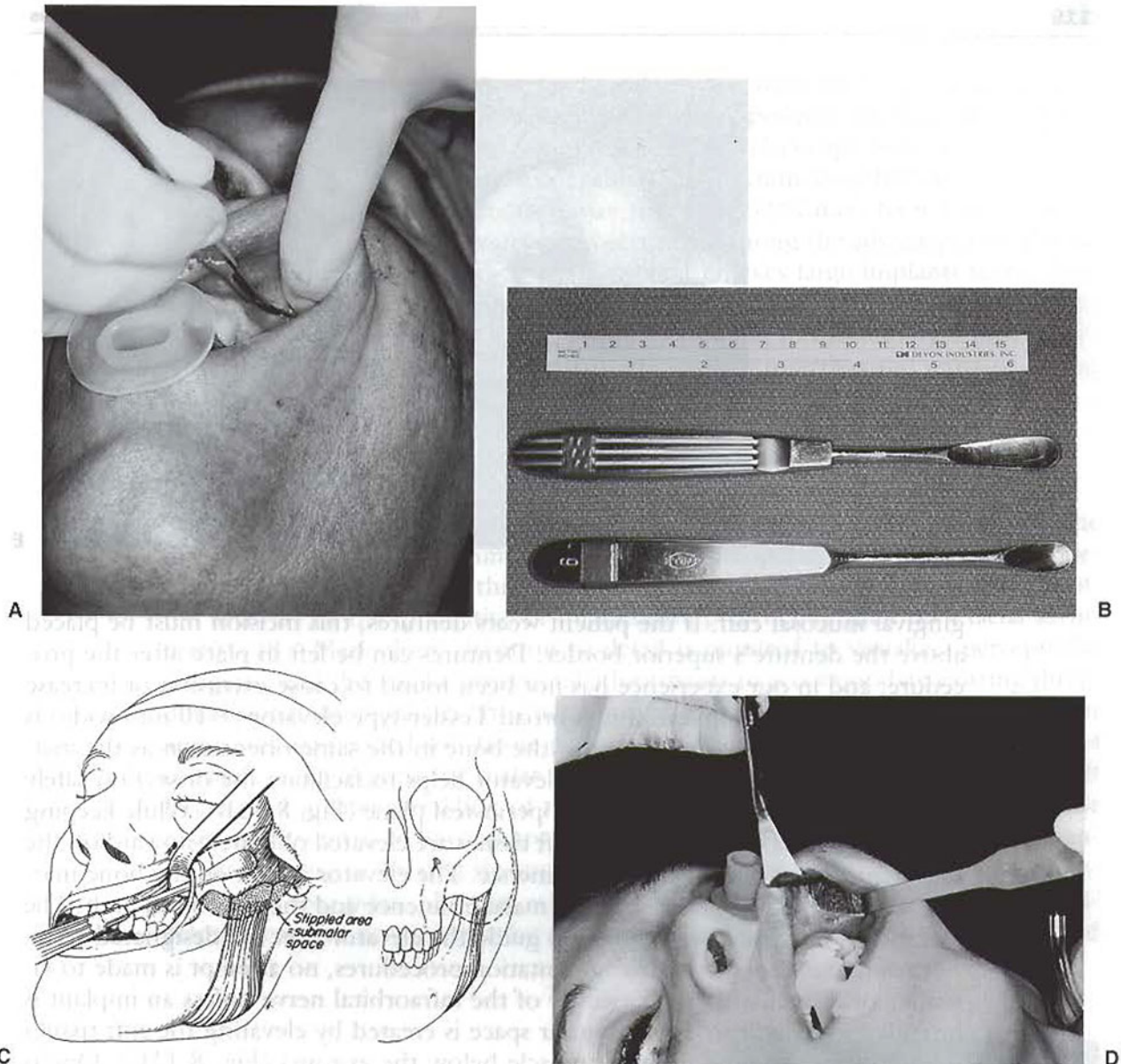


Figure 8-11

A: After injection with local anesthetic, the mucosa is compressed, and a single incision is carried through mucosa and periosteum directly onto bone. The incision is small (1 to 1.5 cm) and is placed over the lateral aspect of the canine fossa and lateral buttress ≥ 1 cm above the buccal-gingival line. **B:** The 9- and 10-mm curved and straight periosteal elevators used for dissection. **C:** This illustration demonstrates the general extent of dissection required for most midfacial implants. The dissection must be sufficiently extended posterolaterally over the zygomatic arch, and/or expanded inferiorly into the submalar space over the tendinous insertions of the masseter muscle so that the implant can be accommodated passively within the pocket. **D:** Direct visual inspection of midfacial structure can be obtained through the intraoral route by retracting the overlying tissues. Sizers or different implants help to determine optimal size, shape, and position of the final implant selected. (The stippled area represents a sizer that has been placed within the pocket.) **E:** Left: The external drawings made on the skin delineate the malar bone and submalar space below. Right: The shape and size of the superimposed implant should roughly coincide with the external topographic defect demarcated before surgery. In this case, the inferior aspect of the implant extends downward to occupy the submalar space. (From ref. 11, with permission.) (continued)

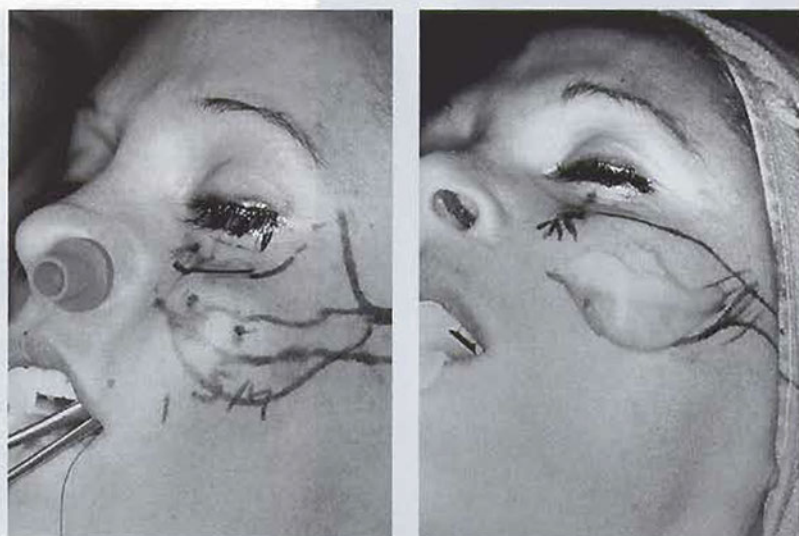


Figure 8-11 (Continued)

gingival mucosal cuff. If the patient wears dentures, this incision must be placed above the denture's superior border. Dentures can be left in place after the procedure, and in our experience has not been found to cause extrusion or increase the incidence of complications. A broad Tessier-type elevator (≈ 10 mm wide) is directed through the incision onto the bone in the same orientation as the incision. A broad rather than narrow elevator helps to facilitate the dissection safely and with relative ease within the subperiosteal plane (Fig. 8-11B). While keeping the elevator directly on bone, the soft tissues are elevated obliquely upward off the maxillary buttress and the malar eminence. The elevator is kept on the bone margin along the inferior border of the malar eminence and the zygomatic arch. The external or free hand is used to help guide the elevator over the designated areas. For routine malar-submalar augmentation procedures, no attempt is made to visualize or dissect within the vicinity of the infraorbital nerve unless an implant is intended for this area. The submalar space is created by elevating the soft tissues inferiorly over the the masseter muscle below the zygoma (Fig. 8-11C). One is able to discern the correct plane of dissection by the glistening white fibers of the masseter tendons by direct vision. It is important to note that these masseteric attachments are not cut and are left completely intact to provide a supporting framework upon which the implant may rest. As the dissection moves posteriorly along the zygomatic arch, the space becomes tighter and is not as easily enlarged as the medial segment. However, part of this space can be opened by gently advancing and elevating the tissues with a heavy, blunt periosteal elevator. It is of utmost importance that the dissection be extended sufficiently so that the implant fits passively within the pocket. A pocket that is too small will force the implant in the opposite direction, causing implant displacement or extrusion (16). Under normal conditions, the pocket is estimated to collapse and obliterate most of the space around the implant within 24 to 48 hours after surgery. Implant selection is aided by observing the actual topographic changes produced by placement of the different implant sizes into the pocket (Fig. 8-11D).

Final implant placement must correspond to the external topographic defects outlined on the face before surgery (Fig. 8-11E). In submalar augmentation, the implant may reside below the zygoma and zygomatic arch, over the masseter ten-

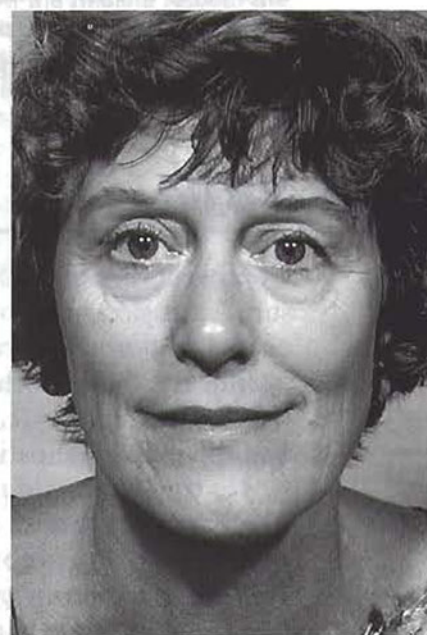don, or it may overlap both bone and tendon. The larger shell-type malar implants reside primarily on bone in a more superior, lateral position and may extend partly into the submalar space. The combined implant will occupy both areas. Any implant placed in patients with noticeable facial asymmetry, thin skin, or an extremely prominent bone structure may require modification to reduce its thickness or length and avoid abnormal projections. Among the advantages of silicone elastomer midfacial implants is flexibility that enables large implants to be compressed through small openings and be able to reexpand within the larger pocket created beyond the incision (17). This avoids having to make a larger incision required for rigid implants and allows ease of implant insertion and removal during the selection process.

Facial Asymmetry

The most difficult task in achieving successful results in facial contouring is the management of facial asymmetry. During the preoperative consultation, a thorough discussion regarding this problem is essential, because most patients are often unaware of the qualitative or quantitative presence of their own facial asymmetry (18). Meticulous attention to detail is required to visualize, perceptually integrate, and then make procedural adjustments to accommodate existing three-dimensional discrepancies. It is not unusual to find adequate malar development and a well-suspended soft-tissue pad with good external contour on one side of the face, and a hypoplastic malar eminence along with relative atrophy of the soft tissues and greater wrinkling of the skin on the other side (Fig. 8-12). In these cases, it is essential to have an applicable selection of implants available and to anticipate carving or altering the implants to adjust to the differences in contour between the two sides. Unusual asymmetries also may require using different implants for each side or shims that are carved from a silicone block that are sutured

Figure 8-12

This patient reveals a complex picture of facial asymmetry. Overall assessment reveals the right side of the face to be significantly narrower in width and to exhibit a relative degree of maxillary-zygomatic hypoplasia as compared with the more prominent malar development on the left side. Adequate soft tissue provides good anterior projection over the left midfacial and submalar area as compared with the relative flattening and lack of soft-tissue substance on the right side. Therefore to balance the face properly, we might anticipate using a combined malar-shell implant on the right side and a malar implant on the left side.



to the posterior surface of the implant to increase the projection of a particular segment of the implant.

Implant Fixation

Once implant position has been established, it is usually necessary to secure the implant. This can be accomplished by a number of different methods. Internal suture fixation relies on the presence of an adjacent stable segment of periosteum or tendinous structure upon which to anchor the implant. Stainless-steel or titanium screws also can be used.

Two methods of external fixation are used to stabilize midfacial implants. The **indirect lateral suspension technique** uses 2-0 nylon sutures wedged on large Keith needles and placed through the implant tail. These needles are then inserted through the pocket and directed superiorly and posteriorly to exit percutaneously posterior to the temporal hairline. The sutures are then tied over a bolster exerting traction on the tail of the implant. This technique is more suitable for malar implants. The **direct method of external fixation** is often used in patients with gross asymmetry or when submalar or combined implants are used. In these situations, the direct external method of fixation will prevent slippage in the immediate postoperative period. With this method, the implants are positioned directly to correspond with marks on the skin that coincide with the two most medial fenestrations of the implant. Symmetric placement of both implants is assisted by measuring the distance from the midline to both right and left medial markings (Fig. 8-13A). The implants are then removed and placed on the skin by lining up the medial fenestration over its corresponding mark. The position of the lateral portion of the implant is then decided by placing a second mark corresponding to the adjacent implant fenestration. A double-armed suture with 1-inch straight needles is then passed through the two medial fenestrations of the implant from a posterior to anterior direction. The needles are advanced through the pocket, passed perpendicularly through the skin, and exit at the respective external markings (Fig. 8-13B). The implant, following the needles, is guided into the pocket. The implant is then secured in place by tying the sutures over bolsters composed of two dental rolls (Fig. 8-13C).

Complications

Complications of facial implants include bleeding, hematoma, infection, exposure, extrusion, malposition, displacement or slippage, fistula, seroma, persistent edema, abnormal prominence, pain, inflammatory reaction, and nerve damage. It is difficult to isolate the cause of the complication, since it is difficult to separate the surgical technique, the surrounding circumstances of the individual operation, and the individual patient factors from the implant material itself.

Extrusion should not occur if the technical rules outlined have been followed. The extended surface area of the larger or extended implants that fit along the midface and mandibular contours minimizes malposition and malrotation. Dissection of the subperiosteal space to create midlateral and posterolateral tunnels in the mandible and the desired pockets in the midface will maintain the im-

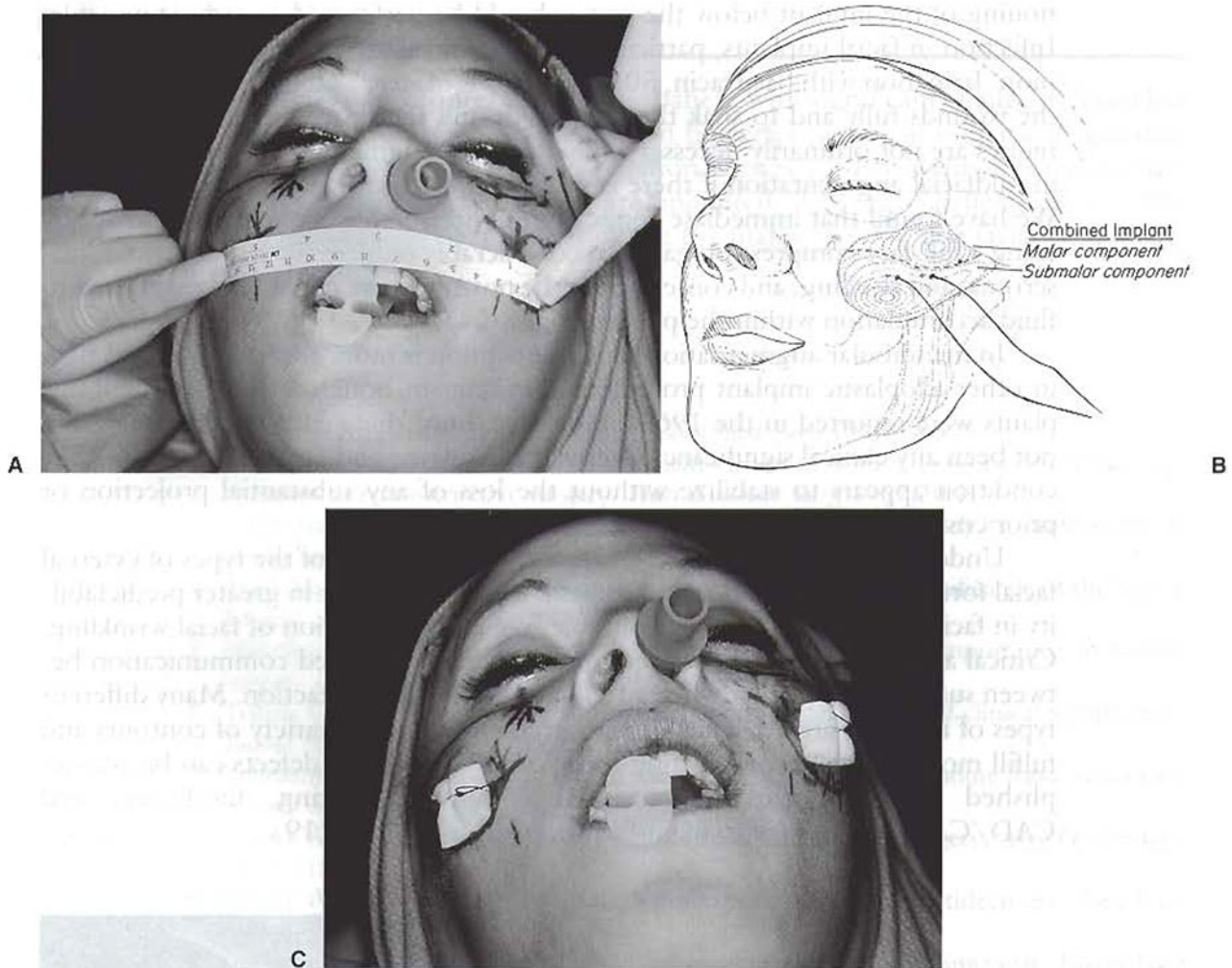


Figure 8-13

A: Symmetric placement is assisted by measuring the distance from the midline to both the right and left marks. A second mark is then placed on the skin, which corresponds to the second, adjacent fenestration, which determines the superior-inferior orientation of the lateral portion of the implant. **B:** A double-armed 2-0 silk suture is passed around the posterior surface of the implant and through the fenestration. From inside the pocket, the needles are passed directly perpendicular to the skin, exiting at the respective external markings, thus providing two-point fixation. [This illustrates the two components (malar and submalar) that form the combined implant.] **C:** The implant is stabilized by tying the suture directly over an external bolster (composed of two cotton rolls). The suture and bolster are removed by the third postoperative day. (From ref. 11, with permission.)

plant in proper position. In mandibular augmentation, the mandibular branch of the facial nerve passes just anterior to the middle portion of the mandible in the midlateral zone. It is important not to traumatize the tissues that overlie this area. Similarly, the temporal branch of the facial nerve passes posterior to the middle aspect of the zygomatic arch, and care also must be exercised when dissecting in this area. Permanent anesthesia of the mental nerve is rare. Temporary anesthesia or paresthesia for several weeks after surgery is not uncommon. If encroachment on the nerve is detected by misplacement or malrotation of the implant, then reposi-

tioning of the implant below the nerve should be performed as early as possible. Infection in facial implants, particularly in silicone elastomer implants, is uncommon. Irrigation with bacitracin, 50,000 units/L of sterile saline, is used to irrigate the wounds fully and to soak the implant during the procedure. Drainage techniques are not ordinarily necessary in mandibular augmentation but may be used in midfacial augmentation if there is more than the normal amount of bleeding. We have found that immediate application of pressure over the entire midface by using a full-face compression garment considerably reduces the risk of hematoma, seroma, and swelling, and consequently the postoperative complications related to fluid accumulation within the pocket (Fig. 8-14).

In mandibular augmentation, bone resorption is more commonly found than in other alloplastic implant procedures. Findings of bone erosion after chin implants were reported in the 1960s. However, since these early reports, there has not been any clinical significance after surveying large audiences of surgeons. The condition appears to stabilize without the loss of any substantial projection or prior cosmetic enhancement.

Understanding the principles of anatomy, observation of the types of external facial forms, and careful attention to basic techniques result in greater predictability in facial contouring and its applicable role in the reduction of facial wrinkling. Critical analysis of the patient's face and precise and focused communication between surgeon and patient will lead to optimal patient satisfaction. Many different types of implants are available for the surgeon to create a variety of contours and fulfill most needs. Reconstructing more complex contour defects can be accomplished by using three-dimensional computer imaging, modeling, and CAD/CAM technology to manufacture custom implants (19).



Figure 8-14

The immediate application of some pressure over the entire midface by using a full-face compression garment has been found to considerably reduce the risk of hematoma, seroma, and swelling.

► Conclusion

Facial-implant procedures provide the patient with significant change in his or her facial appearance. These procedures can be performed as an outpatient operative procedure with local intravenous sedation anesthesia. The ability to produce harmony and proportion to the face are unlimited. Although challenging, very few types of surgical operations can provide the major rewards that facial-contouring procedures offer.

REFERENCES

1. Romm S. Art, love and facial beauty. *Clin Plast Surg* 1987;14:579.
2. Broadbent TR, Mathews VI. Artistic relationships in surface anatomy of the face: application to reconstructive surgery. *Plast Reconstr Surg* 1957;20:1.
3. Gonzalez-Ulloa M, Stevens EF. Senility of the face: basic study to understand its causes and effects. *Plast Reconstr Surg* 1965;36:239.
4. Keen M, Arena S. The surgical anatomy and plastic surgical significance of the buccal fat pad. *Am J Cosmetic Surg* 1989;6:193.
5. Mittelman H. The anatomy of the aging mandible and its importance to facelift surgery. *Facial Plast Surg Clin North Am* 1994;2:301.
6. Tobias GW, Binder WJ. The submalar triangle: its anatomy and clinical significance. *Facial Plast Surg Clin North Am* 1994;2:255.
7. Belinfante LS, Mitchell DL. Use of alloplastic material in the canine fossa-zygomatic area to improve facial esthetics. *J Oral Surg* 1977;35:121.
8. Binder W. Submalar augmentation: an alternative to face lift surgery. *Arch Otolaryngol* 1989;115:797.
9. Binder W. Submalar augmentation: a procedure to enhance rhytidectomy. *Ann Plast Surg* 1990;24:200.
10. Binder W, Schoenrock L, eds. Facial contouring and alloplastic implants. *Facial Plast Surg Clin North Am* 1994;Vol 2, (3) Aug 1994;265-283.
11. Binder WJ. A comprehensive approach for aesthetic contouring of the midface in rhytidectomy. *Facial Plast Surg Clin North Am* 1993;1:231-255.
12. Terino EO. Alloplastic facial contouring by zonal principles of skeletal anatomy. *Clin Plast Surg* 1992;19:487.
13. Flowers RS. Cosmetic blepharoplasty, state of the art. In: *Adv Plast Reconstr Surg* 1992;8:31.
14. Flowers RS. Tear trough implants for correction of tear trough deformity. *Clin Plast Surg* 1993;20:403.
15. Terino EO. Complications of chin and malar augmentation. In: Peck G, ed. *Complications and problems in aesthetic plastic surgery*. New York: Gower Medical Publishers, 1991:182-194.
16. Courtiss E. Complications in aesthetic malar augmentation: discussion. *Plast Reconstr Surg* 1983;71:648.
17. Schultz RC. Reconstruction of facial deformities with alloplastic material. *Ann Plast Surg* 1981;7:434.
18. Gorney M, Harries T. The preoperative and postoperative consideration of natural facial asymmetry. *Plast Reconstr Surg* 1974;54:187.
19. Binder WJ, Kaye A. Reconstruction of posttraumatic and congenital facial deformities with 3-D computer assisted custom-designed implants. *Plast Reconstr Surg* 1994;94:775.