

# Cosmetic Uses of Botulinum Neurotoxin Type A

## An Overview

Andrew Blitzer, MD, DDS; William J. Binder, MD

**C***lostridium botulinum* produces 7 serologically distinct toxins that are designated A, B, C, D, E, and F. They all have similar structure (a dichain with a disulfide bond) and a molecular weight of about 150 d. The light chain is a zinc-dependent metalloprotease, in which the substrate is one of the fusion proteins responsible for docking and ultimately exocytosis of the acetylcholine-containing vesicle. Each serotype light chain cleaves a specific residue of one of these proteins, thus preventing the formation of this docking complex and hence, preventing neurotransmitter exocytosis.<sup>1,2</sup>

Long-term exposure to toxin causes reversible denervation atrophy, and reinnervation occurs through noncollateral sprouting followed by repair of the docking protein, which was cleaved. Clinically, the weakening effects of botulinum neurotoxin (BTX) type A last about 3 to 4 months. Other serotypes have shorter duration of effect.<sup>1,2</sup>

The potency of commercially available toxin is determined through in vitro mouse assays. One unit of BTX-A is defined as the amount of toxin required to kill 50% (LD<sub>50</sub>) of a group of 18- to 20-g female Swiss-Webster mice. The lethal dose in humans is not known. In 1951, Meyer and Eddie estimated that an adult man weighing 104 kg would succumb to an amount of BTX-A 3500 times that needed to cause paralysis and death of mice, suggesting that the LD<sub>50</sub> in humans would be approximately 3500 U. No deaths due to an overdose have been reported in humans, suggesting that the usual maximum dose of 400 U per treatment session on a 3-month interval is safe.<sup>1,2</sup>

Under the trade name Botox (Oculinum, prior to 1992), BTX-A is manufactured in the United States by Allergan Inc (Irvine, Calif) and has been successfully

used worldwide in clinical trials. The US Food and Drug Administration (FDA) dictates standards of production, buffering, stability, potency, and vial size. The European preparation of BTX-A has the trade name Dysport and is distributed by Ipsen Pharmaceuticals (Dublin, Ireland) in the United Kingdom.

Despite the fact that the unit potency of both products is determined with the mouse assay, controversy exists over the potency equivalence between 1 U of Botox and 1 U of Dysport. Reasons for the discrepancy may include differences in assay procedure for the 2 products and differences in physiochemical properties due to manufacturing techniques or dilution. A review of the literature suggests that in clinical use, 1 U of Botox is equivalent to 3 to 4 U of Dysport. Botulinum toxin type B, manufactured by Elan Pharmaceuticals (South San Francisco, Calif) under the name Myobloc, has just been FDA approved for the treatment of cervical dystonia. It also has different dosing units, with the estimated dose comparison being 1 U of Botox equivalent to 50 to 100 U of Myobloc.<sup>1,2</sup>

Botox is available in a standard vial that contains 100 U of toxin. The toxin is shipped from the manufacturer on dry ice and should be stored in a freezer at -5°C (manufacturer's recommendation). Frozen lyophilized toxin is reconstituted with 0.9% non-preserved sterile isotonic sodium chloride (saline) solution to various concentrations, depending on the desired dose.

From Columbia University and the New York Center for Voice and Swallowing Disorders, New York (Dr Blitzer), and the Department of Head and Neck Surgery, University of California, Los Angeles (Dr Binder). Drs Blitzer and Binder have received consultant fees from Allergan Inc, Irvine, Calif, and Dr Blitzer has received research grants from Allergan Inc.



Once familiar with the anatomy of the facial musculature, a tuberculin syringe equipped with a 30-gauge needle is sufficient for most injections into the upper third of the face. Alternatively, other fine muscles of the face as well as the platysma muscle can be targeted most effectively with guidance from an electromyograph (EMG) for greater precision, allowing for the smallest dose while lessening the potential for adverse effects.

For most injections, we use a tuberculin syringe equipped with a 27- or 30-gauge needle. Coated monopolar EMG needles allow for EMG guidance when delivering the toxin into muscles. The fine muscles of the face responsible for facial expression may be targeted most effectively with EMG guidance, allowing for the smallest dose and least adverse effects.

### RISKS AND ADVERSE EFFECTS

Botulinum neurotoxin type A has been used as a therapeutic agent since the late 1970s and has been remarkably safe. Weakness on routine EMG in muscles distal to the injection site has not been reported, but shimmer and jitter on single-fiber EMG and a diminution of the size of type IIB fibers in distant muscles have been reported. There has also been a report of altered cardiovascular reflexes. These physiological abnormalities, however, do not appear to have any clinical significance, and it is not known how long they persist. There is a paucity of data regarding use of BTX-A during pregnancy, and it has not been established whether there are teratogenic effects. Therefore, we recommend not injecting patients who are pregnant or lactating. We recommend treating with caution those patients with neuromuscular junction disorders such as myasthenia gravis, Eaton-Lambert syndrome, and motor neuron disease. Some patients have reported idiosyncratic symptoms such as an itch, rash, or flulike syndrome. Most of the adverse effects are related to weakness of adjacent musculature, causing symptoms such as eyelid ptosis, drooling, and facial asymmetry.<sup>1-4</sup>

Resistance is characterized by absence of any beneficial effect and the lack of muscle atrophy following injection of the toxin. Antibodies against the toxin are presumed to be responsible for most cases of true nonresponders. Many cases of nonresponse are related to poor technique in placing the toxin in the appropriate muscles. True immunoresistance may be tested immunologically, with a variation of the mouse lethality assay. Patients who develop BTX-A resistance may benefit from injections of other serotypes. To minimize the chance for immunoresistance, (1) use the smallest possible effective dose and (2) extend the interval between treatments for as long as possible to minimize the number of exposures to the toxin.<sup>1,5</sup>

Scott<sup>6</sup> reported the first clinical use of BTX-A for strabismus. He then extended its use for blepharospasm. Since then, it has become the treatment of choice for focal dystonias of most types, including torticollis, oromandibular dystonia, and spasmodic dysphonia. It has also been found very useful for many other hyperfunctional conditions such as spasticity, hemifacial spasm, gastrointestinal sphincter spasms, migraine and tension head-

aches, hyperhidrosis, management of tics and tremor, and temporomandibular disorders. During the treatment of patients with facial dystonia and hemifacial spasm, we and others observed a notable cosmetic benefit from weakening of the underlying musculature. Since this early observation, several cosmetic clinical trials have been carried out, and there is a large growing experience in the use of BTX-A for cosmetic enhancement.<sup>1,7-10</sup>

### COSMETIC INDICATIONS

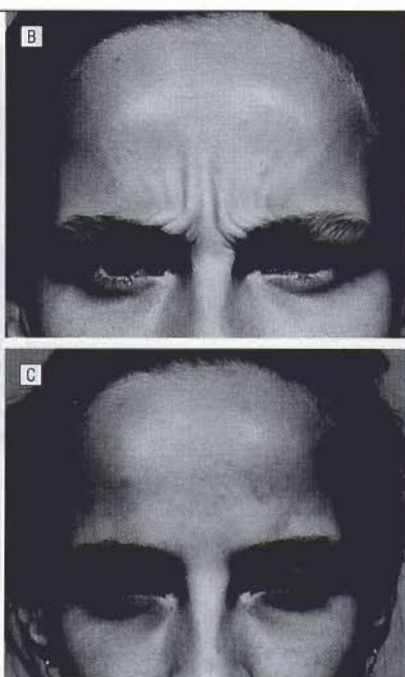
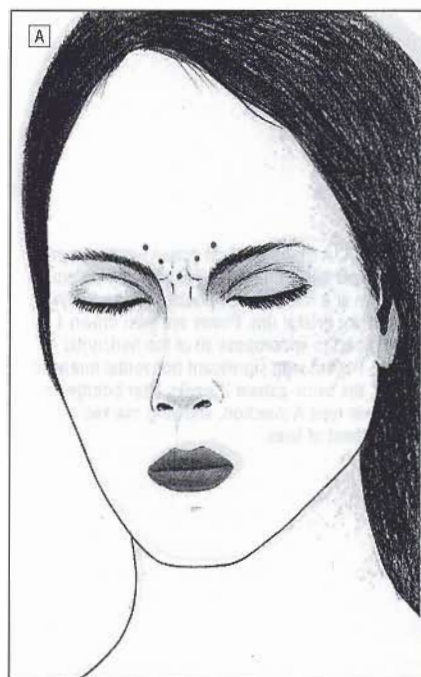
Facial lines and wrinkles have a multifactorial etiology including sun exposure, loss of dermal elastic fibers, skin atrophy, and excessive muscle activity. Hyperfunctional facial lines are caused by the skin pleating when the underlying muscles contract, which is best illustrated when there is a loss of these hyperfunctional lines and creases with the resultant smooth skin surface in patients who had strokes, facial nerve injuries, or Bell palsy. Hyperfunctional facial lines are distressing to patients because they are often misinterpreted as anger, fear, fatigue, melancholia, and aging. Botulinum toxin therapy for patients with hemifacial spasm, facial tics, or facial dystonia produces a diminution of hyperfunctional facial lines. Patients having had unilateral injections for neurologic or neuromuscular disorders often return asking for the contralateral side to be injected to give a more symmetrical and youthful appearance. We therefore first reported the cosmetic effect of the toxin in patients who were receiving injections for neurologic disease. In a prospective, double-blind study, we demonstrated the efficacy of toxin injections for hyperfunctional facial lines.<sup>11,12</sup> In 1998-1999, Carruthers<sup>13</sup> and Carruthers and Carruthers<sup>14,15</sup> also described a cosmetic benefit of facial injections of botulinum toxin.

### TECHNIQUE

The materials necessary for botulinum toxin treatment are toxin, a standard freezer, sterile saline solution without preservative, syringes, alcohol swabs, small-gauge needles (30 gauge), and in many cases a small EMG machine and a monopolar needle. The standard vial of Botox contains 100 U of toxin. The toxin is shipped from the manufacturer on dry ice and should be stored at -20°C (our recommendation). The frozen, lyophilized toxin is reconstituted with sterile, nonpreserved saline solution. The doses of toxin are typically calculated in 0.1-mL aliquots. Therefore, the more saline solution added to the vial, the smaller the dose per 0.1 mL. Typically, we use 4 mL of saline solution per vial (making 2.5 U/0.1 mL) or 2 mL of saline solution (making 5 U/0.1 mL).

The patients are first evaluated with a thorough review of their medical history, medications, and prior cosmetic surgery. A detailed discussion of the patient's facial lines and the botulinum toxin technique and expected effect then takes place. The patient is made aware that the hyperfunctional muscular lines are best treated with botulinum toxin to prevent the contraction of the facial muscles that cause these lines. Redundant skin folds and lines or fine rhytids present at rest. Lines are best treated with chemical peels and/or laser resurfacing. Persistent





**Figure 1.** A, Diagram showing injection sites for glabellar lines. B, Patient with glabellar lines caused by significant corrugator muscle contraction; C, the same patient 2 weeks after botulinum neurotoxin type A (Botox) injection for glabellar lines.

lines may be treated with injectable fillers such as collagen. Often a patient's facial line characteristics require a combination of these techniques to achieve a therapeutic effect.

Standard photographs are taken of the patient's face at rest and with activity. The patient's lines, skin condition, and any scars and/or asymmetry are noted in the medical chart. An informed consent is obtained for each patient.

The patient's face is then marked for the areas of maximum muscle pull that are causing the bothersome hyperfunctional lines. A diagram of the points to be injected is drawn or photographed for future reference. The skin can then be iced or treated with topical anesthetic creams to decrease the discomfort associated with skin penetration by the needle. The toxin is drawn up in a tuberculin syringe with a 30-gauge needle for injection. If an EMG needle is used, it is then connected to the EMG machine and ground and reference leads are placed on the face or in the supraclavicular area. The needle is placed through the overlying skin at about a 30° angle to impale the previously marked muscle for injection. The patient is then instructed to accentuate the specific facial expression that produces the unwanted line. If the needle is an active part of the muscle, a loud burst of activity will be heard on the speaker of the EMG machine. If a distant signal is obtained (low-frequency, dull sound) the needle should be moved until it is in a maximal position, and the toxin is then injected. This technique is repeated at each marked area for injection. The injections in the periorbital area are often done without EMG guidance, using a tuberculin syringe and a 30-gauge needle. After the injections, the patient is asked not to rub or massage the injected area for several hours to avoid excess diffusion to adjacent muscles, which might cause excessive and unintended weakness of these muscles.

## SPECIFIC INJECTION SITES

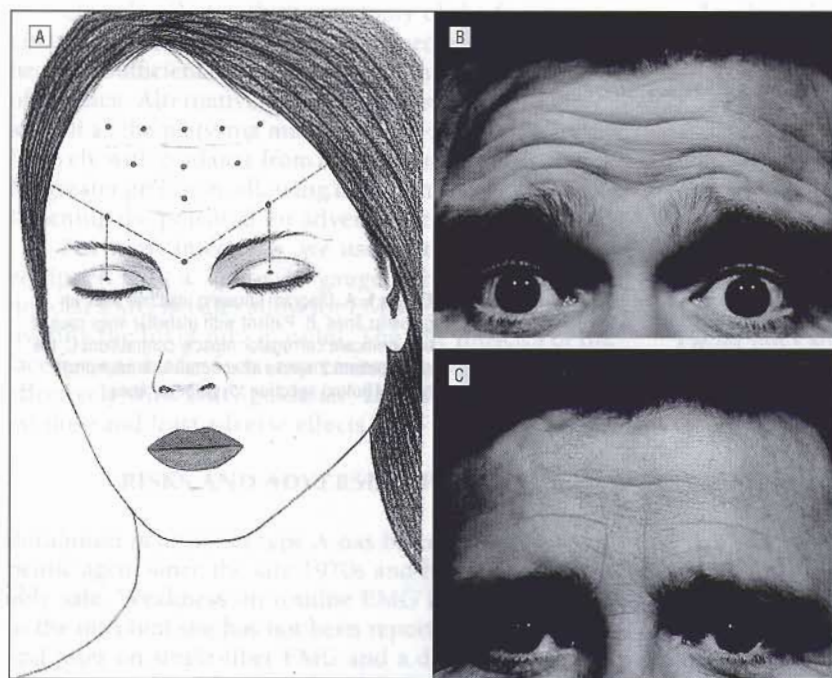
### Glabellar Lines

The glabellar injections manage the hyperactivity of the corrugator and procerus muscles (**Figure 1**). In general, we inject 5 sites with 12.5 to 20 U. The injection of the corrugator muscle should go out lateral enough to encompass the whole muscle without going past the mid-pupillary line. Injections that are placed too far laterally and too close to the brow may lead to brow ptosis or lid ptosis from levator weakness. Too much lateral extension or injection too close to the brow may lead to weakness of the levator muscle and ptosis. The corrugator muscle can be injected with several individual injections or can be "skewered" with EMG guidance and then injected on withdrawal of the needle.

### Horizontal Forehead Lines

The frontalis muscle injections manage the hyperactivity of the frontalis muscle, which pulls the forehead skin in a vertical direction, creating horizontal pleats in the overlying skin (**Figure 2**). These should be marked about every 1 to 1.5 cm apart across the forehead. We inject 2.5 to 5 U at each site marked. The toxin should not be injected close to the brow because this may cause brow ptosis or even levator ptosis. Laterally, the toxin injection sites are raised away from the brow to leave some functional frontalis muscle, allowing the patient some expressive function of the lateral brow without wrinkling in most of the forehead skin. Most of our patients prefer to have some residual expressive movement of the brow. If there are several rows of deep hyperfunctional lines of the forehead, a second row of toxin injections is planned. The forehead is then treated with an ice pack and/or topi-





**Figure 2.** A, A triangle is first drawn with apex at a central point between the medial brows. Two points are drawn at a midpupillary position, 1 cm above the superior orbital rim. Points are then drawn 1 to 1.5 cm apart to encompass all of the horizontal lines. B, Patient with significant horizontal forehead lines; C, the same patient 2 weeks after botulinum neurotoxin type A injection, showing marked improvement of lines.

cal anesthetic cream. The underlying frontalis muscle is then injected either with a 30-gauge needle or with EMG guidance to assure more accurate needle placement.

#### Brow Position

The position of the brow is directly related to the balance of the brow elevators (primarily the frontalis), the brow depressors (primarily the orbicularis oculi), and the brow medializer (the corrugator, procerus, and depressor supercillii). To arch the eyebrow, the medial muscles are weakened (including the corrugator, procerus, and depressor supercillii). This allows the lateral frontalis to be relatively unopposed and pull the lateral brow upward. If there is not enough elevation of the lateral brow, 1 to 2 U of toxin can be given at the junction of the temporal line and the supraorbital rim to weaken the depressor (orbicularis oculi) and allow the elevator (lateral frontalis) to reposition the brow upwards.

If one brow is higher than the other, the patient needs to consider which brow is cosmetically more appealing. If it is the brow with the lower position, the frontalis on the contralateral side is injected to lower that brow; if it is the raised brow, the lateral portion of the orbicularis oculi on the contralateral side is injected to raise the brow.<sup>15-17</sup>

#### Crow's-Foot Lines

These lines are due to the hyperactivity of the lateral orbicularis oculi muscle (**Figure 3**). This muscle functions in the closure of the eyelids, blinking, and squinting. Excessive lateral activity will excessively pleat the lateral orbital facial skin, creating crow's-feet. Small amounts of toxin can weaken the lateral aspect of this muscle, thereby decreasing the wrinkling of the skin, without interfering with eye blinking or closure. To accomplish this, marks are made at the lateral canthal line 1 cm from the lateral

canthus (this is usually at the bony orbital rim). The patient is asked to squint, and if there are hyperfunctional lines above the mark, a second mark is made in the superior area. The squint lines below the mark are then addressed, with another mark inferiorly and following the curvature of the bony orbital rim. Another mark can be made inferiorly, but not past the midpupillary line because this may interfere with the pumping of tears and cause epiphora. If the inferior injection is placed too low, the zygomaticus muscles may be weakened, causing a change in the smile. Most of these injections can be given without EMG guidance, using a standard 30-gauge needle. We use 2.5 to 5 U per site marked.

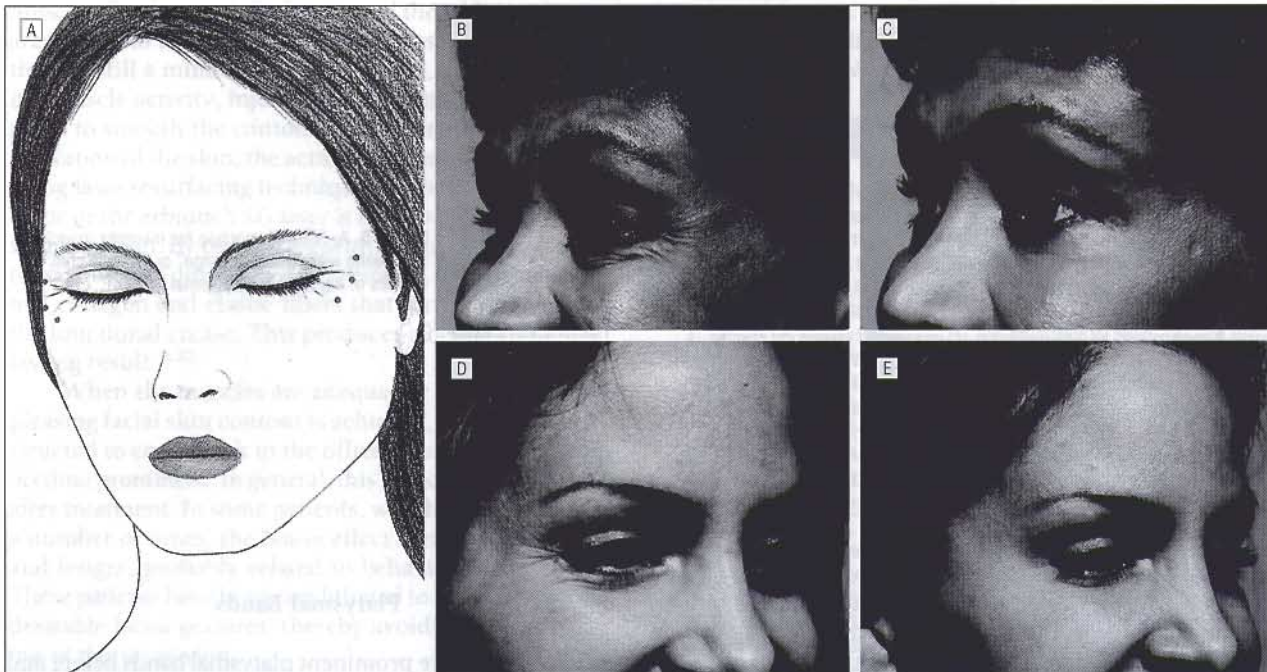
#### Nasal Scrunch or "Bunny" Lines

These lines are due to excessive contracture of the nasalis muscle (**Figure 4A**). On smiling, these individuals develop radial lines along the lateral dorsum of the nose, and they may radiate as far as the lower border of the lower lateral cartilage of the alae. The injection should be given superior to the nasofacial groove to avoid the levator labii superioris alaeque nasi (to avoid ipsilateral lip ptosis) and the angular vein superiorly. Our usual dose is 5 U in each site.

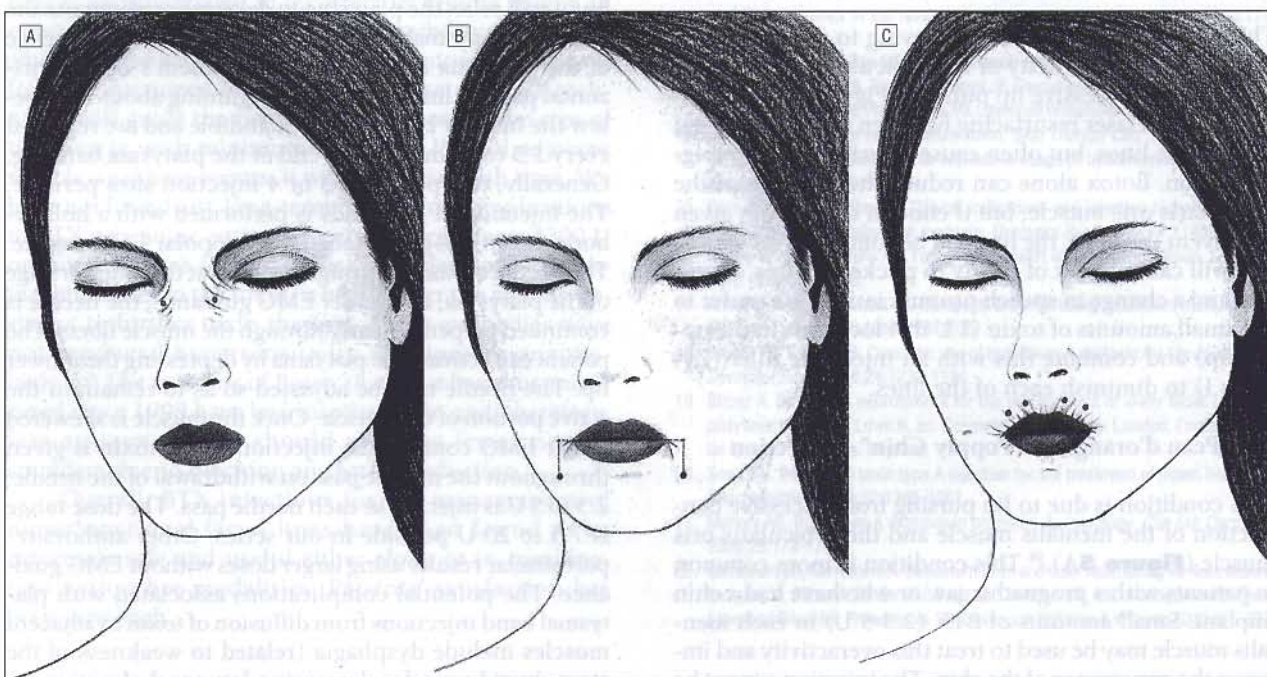
#### Nasolabial Lines

These lines are produced along the connection of the orbicularis oris muscle and all of the lip elevators such as the zygomaticus minor and major, the levator labii superioris, and the levator anguli oris. This line is deepened with loss of part of the submalar fat pad. The line disappears when the facial nerve is not functioning as in patients with a Bell palsy. As the nerve function returns, the line returns. Weakening of the lip elevator muscles and the orbicularis oris muscle will eliminate the line but





**Figure 3.** A, Sites of injections for lateral orbital lines or crow's-feet. B, Patient with multiple lateral orbital lines or crow's-feet lines prior to botulinum neurotoxin type A (Botox) injection; C, the same patient 2 weeks after Botox injection for lateral orbital lines. D, Patient with noticeable lateral orbital lines or crow's-feet; E, the same patient 2 weeks after Botox injection for crow's-feet.



**Figure 4.** A, Sites of injection for lateral nasal or "bunny" scrunch lines; B, sites of injection for lateral oral or "marionette" lines; C, sites of injection for perioral or "lipstick" lines.

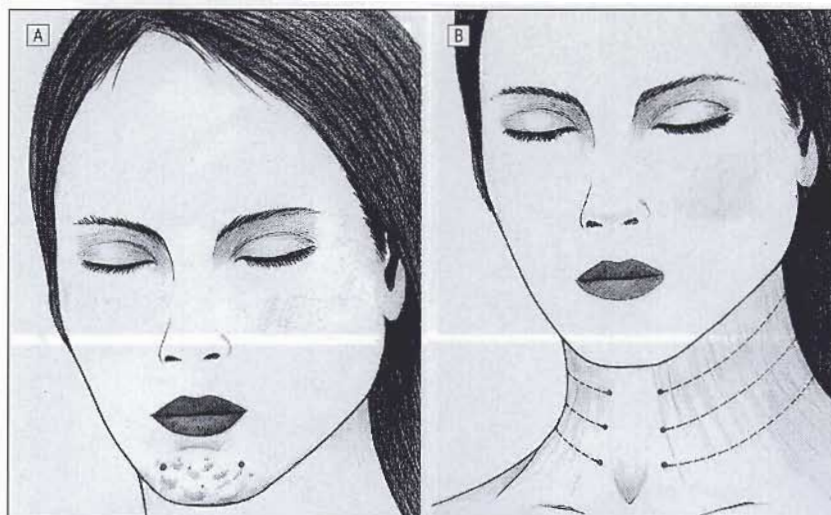
leave the patient with an asymmetric smile, a droopy lip, and possible drooling. In our practice, we prefer to treat these lines with injectable fillers.

#### "Marionette" Lines

These are usually the result of hyperactivity of the depressor anguli oris muscle at its connection to the edge

of the orbicularis oris muscle (Figure 4B). A weakening of the depressor anguli oris may decrease or eliminate the lines. Carruthers and Carruthers<sup>15</sup> have described a technique for best managing these lines. In this technique, a point is drawn 7 to 10 mm lateral to the oral commissure and 8 to 10 mm inferior to this point; this inferior-lateral point should be in the depressor muscle. A dose of 2 to 4 U in 0.1 mL is given. An excessive dose or vol-





**Figure 5.** A, Sites of injection for mentalis muscle in patients with "peau d'orange" or "popply chin"; B, sites of injection for platysmal bands.

ume may cause a weakening of the orbicularis oris, producing a change in the ability to pucker the lips, causing drooling and/or a change in speech. In some cases a combination of injectable filler and Botox yields the best results.<sup>13,15</sup>

### "Lipstick" Lines

These lines, which are very annoying to many women, are from the overactivity of the orbicularis oris muscle, usually from excessive lip pursing (Figure 4C). Chemical peels and laser resurfacing has been used to try to get rid of these lines, but often cause scarring and hypopigmentation. Botox alone can reduce the function of the orbicularis oris muscle, but if enough of a dose is given to prevent the lines, the lips will be somewhat adynamic and will cause a lack of ability to pucker the lips, drooling, and a change in speech pronunciation. We prefer to use small amounts of toxin (1 U in 4 locations in the upper lip) and combine this with an injectable filler (Zyderm I) to diminish each of the lines.

### Peau d'orange or "Popply Chin" Correction

This condition is due to lip pursing from excessive contraction of the mentalis muscle and the orbicularis oris muscle (Figure 5A).<sup>18</sup> This condition is more common in patients with a prognathic jaw or who have had a chin implant. Small amounts of BTX (2.5-5 U) in each mentalis muscle may be used to treat this overactivity and improve the appearance of the chin. The injection cannot be given higher than the halfway point between the vermilion border of the lower lip and the inferior edge of the mentum and 0.5 to 1 cm medial to the oral commissure. If the injection is given too high or too much toxin is used, it will excessively weaken the orbicularis oris, causing a decreased ability to pucker the lips and may cause drooling while drinking fluids. It may also change speech by interfering with plosive and fricative speech elements. The EMG technique is used, and the patient is asked to pucker her lips. When the needle is in a very active place within the muscle, the toxin is injected.

### Platysmal Bands

Patients who have prominent platysmal bands before and after face-lift procedures may also benefit from injections of Botox, but without a submental incision commonly used for muscle plication (Figure 5B). The toxin will not get rid of excess fat or skin in the submental area, but it will relax the platysma to decrease or eliminate the unsightly platysmal bands. The anterior and posterior edge of the platysma is marked on the patient's neck. Horizontal parallel lines are drawn, beginning about 2 cm below the inferior border of the mandible and are repeated every 1.5 to 2 cm until the end of the platysma banding. Generally, this produces 3 or 4 injection sites per side. The injection of the bands is performed with a hollow-bore, 1.5-in, 27-gauge, coated monopolar EMG needle. The needle is passed through the skin at the anterior edge of the platysma, and under EMG guidance, the needle is continued perpendicularly through the muscle fibers. The patient can activate the platysma by depressing their lower lip. The needle may be adjusted so as to remain in the active portion of the muscle. Once the muscle is skewered under EMG control, the injection of the toxin is given throughout the muscle pass on withdrawal of the needle; 2.5 to 5 U is injected in each needle pass. The dose range is 7.5 to 20 U per side in our series. Other authors report similar results using larger doses without EMG guidance. The potential complications associated with platysmal band injections from diffusion of toxin to adjacent muscles include dysphagia (related to weakness of the sternohyoid muscles decreasing laryngeal elevation on swallowing) and changes in voice pitch (from weakness of the cricothyroid muscles). The latter may be very noticeable in singers.<sup>18-20</sup>

### POSTINJECTION FOLLOW-UP

After the injections are complete, the patients are asked to return to the office after 2 weeks for reevaluation. New photographs are taken. If the hyperfunctional lines are still bothersome to the patient, additional toxin is injected into the remaining hyperactive portion of the



muscle. The dose and the location of the additional toxin are related to the areas of maximal persistent activity. If there is still a minor crease in the skin, but no underlying muscle activity, injections of a filler material can be given to smooth the contour of the skin. After adequate relaxation of the skin, the actinic lines can also be treated using laser resurfacing techniques. Either the carbon dioxide or the erbium:YAG laser is used to remove thinned, wrinkled skin. By pretreating with Botox, the hyperfunctional lines are diminished or removed, and the new dermal collagen and elastic fibers that form will not be in the functional crease. This produces a better and longer lasting result.<sup>21,22</sup>

When the muscles are adequately weakened and a pleasing facial skin contour is achieved, the patient is instructed to come back to the office when the lines again become prominent. In general, this is about 4 to 6 months after treatment. In some patients, who have been treated a number of times, the Botox effect seems to last longer and longer, probably related to behavior modification. These patients have been conditioned to avoid certain undesirable facial gestures, thereby avoiding excess pleating of the facial skin.

Complications of toxin injections may lead to mild bruising or local pain related to the injection needle. There also may be weakness of adjacent muscles related to diffusion of the toxin. The amount of diffusion and weakness is usually related to incorrect technique and/or an excessive dose. To minimize this possibility, we use the smallest dose and volume necessary. Initially, until sufficient experience is acquired, the use of EMG technique will guide the needle into the most active area of the muscle with minimum diffusion. If local adjacent muscle weakness occurs, it will disappear with time. We have not found any long-term hazards or complications of BTX use. Some patients receiving large doses (300 U or more, such as for torticollis) have developed blocking antibodies to the toxin, which render the patients resistant to further toxin therapy. These antibodies have not produced hypersensitivity reactions or anaphylaxis.<sup>1,2,5</sup> The new lots of Botox that have been manufactured since 1998 have less inactive toxin and, therefore, less antigen, which should produce fewer nonresponders due to blocking antibody production.

Overall, BTX injections for the management of hyperfunctional facial lines have been found to be extremely safe and useful either alone or in combination with other modalities. Patients' satisfaction has been very high.

Accepted for publication November 14, 2001.

Corresponding author: Andrew Blitzer, MD, DDS, 425 W 59th St, New York, NY 10019.

## REFERENCES

- Blitzer A, Sulica L. Botulinum toxin: basic science and clinical uses in otolaryngology. *Laryngoscope*. 2001;111:218-226.
- Brin MF. Botulinum toxin therapy: basic science and an overview of other therapeutic applications. In: Blitzer A, Binder WJ, Boyd JB, Carruthers A, eds. *Management of Facial Lines and Wrinkles*. Philadelphia, Pa: Lippincott Williams & Wilkins; 2000:279-302.
- Sanders DB, Massey EW, Buckley EG. Botulinum toxin for blepharospasm: single-fiber EMG studies. *Neurology*. 1986;36:545-547.
- Girlanda P, Vita G, Nicolosi C. Botulinum toxin therapy: distant effects on neuromuscular transmission and autonomic nervous system. *J Neurol Neurosurg Psychiatry*. 1992;55:844-845.
- Greene P, Fahn S, Diamond B. Development of resistance to botulinum toxin A in patients with torticollis. *Mov Disord*. 1994;9:213-217.
- Scott AB. Botulinum toxin injection into extraocular muscles as an alternative to strabismus surgery. *Ophthalmology*. 1980;87:1044-1049.
- Blitzer A, Brin MF, Stewart CF. Botulinum toxin management of spasmodic dysphonia (laryngeal dystonia): a 12 year experience in more than 900 patients. *Laryngoscope*. 1998;108:1435-1441.
- Blitzer A, Brin MF, Greene PE, Fahn S. Botulinum toxin injection for the treatment of oromandibular dystonia. *Ann Otol Rhinol Laryngol*. 1989;98:93-97.
- Brin MF, Fahn S, Moskowitz C, et al. Localized injections of botulinum toxin for the treatment of focal dystonia and hemifacial spasm. *Mov Disord*. 1987;2:237-254.
- Binder W, Brin MF, Blitzer A, Schoenrock L, Pagoda J. Botulinum toxin type A (Botox) for treatment of migraine headaches: an open label study. *Otolaryngol Head Neck Surg*. 2000;123:669-676.
- Blitzer A, Brin MF, Keen MS, Aviv JE. Botulinum toxin for the treatment of hyperfunctional lines of the face. *Arch Otolaryngol Head Neck Surg*. 1993;119:1018-1023.
- Blitzer A, Binder WJ, Brin MF. Botulinum toxin injections for facial lines and wrinkles: technique. In: Blitzer A, Binder WJ, Boyd JB, Carruthers A, eds. *Management of Facial Lines and Wrinkles*. Philadelphia, Pa: Lippincott Williams & Wilkins; 2000:303-313.
- Carruthers A. Update on botulinum toxin. *Skin Therapy Lett*. 1999;4:1-2.
- Carruthers J, Carruthers A. The adjunctive usage of botulinum toxin. *Dermatol Surg*. 1998;24:1244-1247.
- Carruthers A, Carruthers J. Clinical indications and injection technique for the cosmetic use of botulinum A exotoxin. *Dermatol Surg*. 1998;24:1189-1194.
- Huang W, Rogachefsky AS, Foster JA. Browlift with botulinum toxin. *Dermatol Surg*. 2000;26:55-60.
- Ahn MS, Catten M, Maas CS. Temporal brow lift using botulinum toxin A. *Plast Reconstr Surg*. 2000;105:1129-1135.
- Brandt FS, Bellman B. Cosmetic use of botulinum A exotoxin for the aging neck. *Dermatol Surg*. 1998;24:1232-1234.
- Blitzer A. Botulinum neurotoxin A for the management of lower facial lines and platysmal bands. In: Lowe N, ed. *Cosmetic Dermatology*. London, England: Martin Dunitz Publishers. In press.
- Song KH. Botulinum toxin type A injection for the treatment of frown lines. *Ann Pharmacother*. 1998;32:1365-1367.
- Markey AC. Botulinum A exotoxin in cosmetic dermatology. *Clin Exp Dermatol*. 2000;25:173-175.
- Carruthers JA, Carruthers A. Botulinum toxin and laser resurfacing for lines around the eyes. In: Blitzer A, Binder WJ, Boyd JB, Carruthers A, eds. *Management of Facial Lines and Wrinkles*. Philadelphia, Pa: Lippincott Williams & Wilkins; 2000:315-333.