

# FACIAL PLASTIC SURGERY

Official Journal of the European Academy of Facial Plastic Surgery

**Editors-in-Chief**

Anthony P. Sclafani, M.D., F.A.C.S.

Werner Heppt, M.D., Ph.D.



**The Aging Face 2011**

Guest Editor  
Mary Lynn Moran, M.D.

# Facial Rejuvenation and Volumization Using Implants

William J. Binder, M.D., F.A.C.S.<sup>1</sup>

## ABSTRACT

Whereas traditional concepts of facial aging focus on the descent of soft tissue secondary to gravitational effects, it is now well established that volumetric changes involving different levels of soft tissue loss reveal craniofacial skeletal deficiencies that, together, contribute to the changes evident in the aging face. Thus, effective facial rejuvenation requires a comprehensive paradigm that identifies and addresses all anatomic elements involved in the aging process. Contemporary practices in facial rejuvenation have expanded far beyond the rhytidectomy procedure to involve deeper and more fundamental levels of dissection for the purpose of elevating and replacing volume. Alloplastic implants offer a long-term, multidimensional solution to facial rejuvenation by concomitantly augmenting skeletal deficiency, restoring lost soft tissue volume, and smoothing irregularities in the facial contour. Facial augmentation using implants represents a straightforward, simple procedure with minimal risks and long-lasting benefits. By applying accurate and judicious techniques for preoperative analysis, selecting the appropriate implant, and with correct surgical placement of the implants, the facial plastic surgeon can achieve successful facial volumization and restore the youthful appearance of the aging patient.

**KEYWORDS:** Facial volumization, midface implants, malar, submalar, aesthetic facial implants

Successful rejuvenation of the aging face entails a multidimensional approach to correcting volumetric changes involving the skin and soft tissue.<sup>1,2</sup> Facial aging results from soft tissue atrophy and resorption of the bony skeleton, which leads to losses in soft tissue volume and laxity of the overlying skin.<sup>3</sup> Recent reliance on "less invasive" surgical and nonsurgical rejuvenation techniques, however, has tended to minimize the key role of the skeletal structure in time-proven soft tissue procedures. On the contrary, achieving optimal, longer-lasting cosmetic results requires knowledge of how the aging process impacts all levels of the facial elements, including

the skin, soft tissue, and bone structure. These elements themselves share intricate interactions and bear differential effects of aging, which in turn influence aesthetic outcomes. Contemporary face-lift surgery using plication or imbrication of the superficial musculoaponeurotic system (SMAS) or deep plane translocation techniques have all evolved for the purpose of elevating and restoring volumetric mass and changing the shape of the face. However, relying on these techniques as a sole procedure, at any one time during the aging process, may harbor inherent limitations that frequently result in suboptimal, short-lived aesthetic effects.<sup>4</sup> Alloplastic facial implants

<sup>1</sup>Division of Head and Neck Surgery, David Geffen School of Medicine at UCLA, Beverly Hills, California.

Address for correspondence and reprint requests: William J. Binder, M.D., F.A.C.S., 120 S. Spalding Drive, S. 340, Beverly Hills, CA 90212 (e-mail: wjbmd8@aol.com).

The Aging Face 2011; Guest Editor, Mary Lynn Moran, M.D.

Facial Plast Surg 2011;27:86-97. Copyright © 2011 by Thieme Medical Publishers, Inc., 333 Seventh Avenue, New York, NY 10001, USA. Tel: +1(212) 584-4662.

DOI: <http://dx.doi.org/10.1055/s-0030-1270421>.

ISSN 0736-6825.



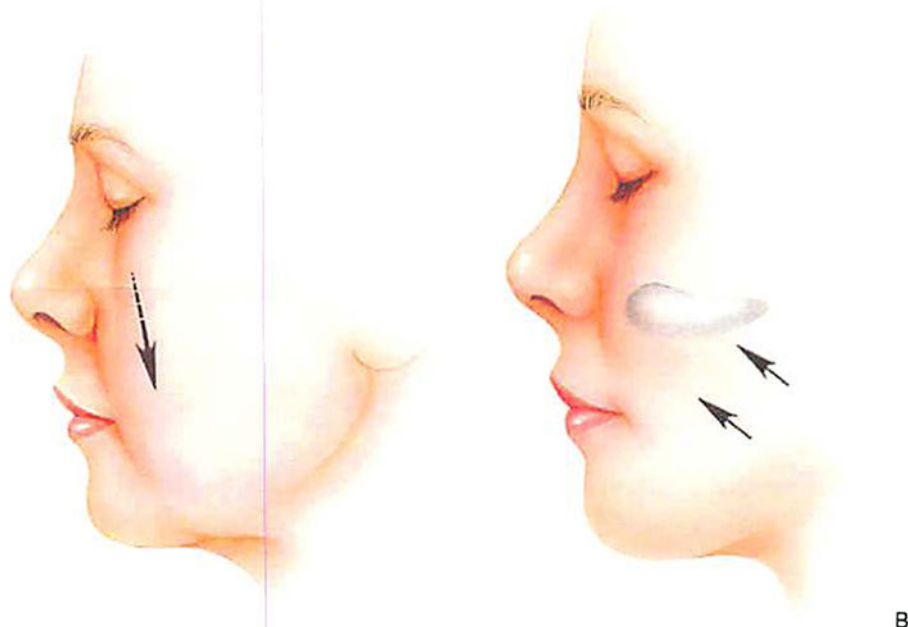can address age-related changes on several levels and offer a long-term solution for augmenting skeletal deficiency, restoring lost soft tissue volume, and smoothing irregularities in the facial contour. For the appropriate candidate, midface implants offer many benefits and advantages either as an alternative method or adjunctive role in facial rejuvenation procedures.

### BACKGROUND AND BENEFITS OF MIDFACE AUGMENTATION

Although early work in aesthetic surgery recognized that changing the overall shape of the face could improve the appearance, midface augmentation was first launched by Binder in the 1980s as an independent method for facial rejuvenation.<sup>3</sup> Together with the development of early midface implant prototypes, Binder's emphasis on the importance of volume restoration as a significant component of facial aesthetics represents a key contribution in the area of facial rejuvenation. It is now well understood that the midface not only descends during the aging process but is also accompanied by soft tissue atrophy in multiple planes. Therefore, augmenting the soft tissue and skeletal foundation can achieve rejuvenating effects surpassing those attained by suspension techniques alone. By restoring lost facial soft tissue volume and increasing the anterior projection of the area, midface

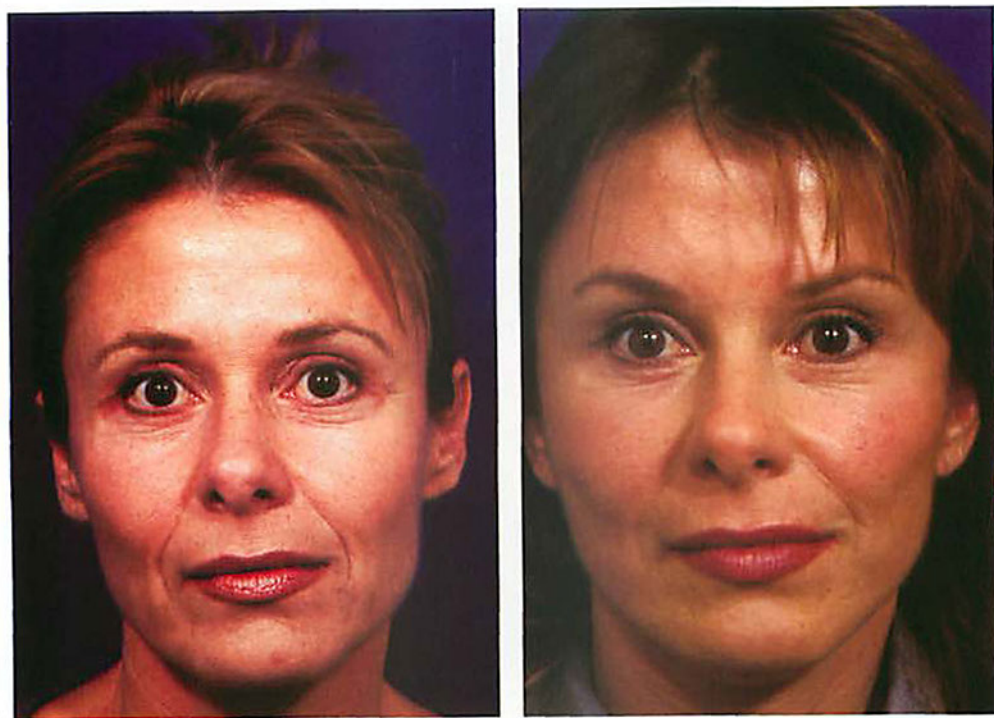augmentation reduces midface laxity and decreases the depth of the nasolabial folds (Figs. 1 and 2). Combined with the rhytidectomy procedure, midface augmentation can soften the sharp angles and depressions of the aged face, rendering a more natural "unoperated" appearance (Fig. 3).

It should be emphasized that all methods used for midface rejuvenation, such as the subcutaneous or deep plane face-lift and subperiosteal face-lift with or without suspension apparatus, address one anatomic level or problem.<sup>5-10</sup> However, any single one of these techniques may fail to adequately address the underlying pathophysiology of midface aging. For example, both the subperiosteal midface lift and deep plane rhytidectomy, while improving the midface via suspension of soft tissue, cannot replace age-related losses of deep or superficial soft tissue. In fact, subcutaneous face-lift surgery, without addressing the SMAS, may have detrimental "skeletonizing" effects in patients who simultaneously exhibit significant losses in midfacial volume and extremely prominent bone structure.<sup>3</sup> Other methods for midface rejuvenation, such as soft tissue fillers, including hyaluronic acids, calcium hydroxylapatite, and collagen, can efface the nasolabial fold but seldom yield predictable, long-lasting aesthetic effects when significant volume enhancement is required.<sup>3</sup> When large amounts of material are injected into soft tissue for the purpose of facial contouring, an



**Figure 1** By providing an anterior "scaffolding," midface implants achieve a suspensory effect that augments the facial skeleton and distributes the soft tissue in a more favorable position. The net effect relocates the soft tissue to a more anterosuperior position that replenishes soft tissue volume and restores the hollow regions of the midface. (From Binder WJ, Kim BP, Azizzadeh B. Aesthetic midface implants. In: Azizzadeh B, Murphy MR, Johnson CM, eds. *Master Techniques in Facial Rejuvenation*. Philadelphia, PA: Saunders; 2007:197-215. Reprinted with permission.)





**Figure 2** (A) Preoperative view of a 45-year-old patient exhibiting midfacial soft tissue volume loss restored with use of submalar augmentation. (From Binder WJ, Kim BP, Azizzadeh B. Aesthetic midface implants. In: Azizzadeh B, Murphy MR, Johnson CM, eds. *Master Techniques in Facial Rejuvenation*. Philadelphia, PA: Saunders; 2007:197–215. Reprinted with permission.)

end point is easily reached where the intended expansion of the area by the filling agent will migrate into adjacent areas that might reduce rather than enhance the aesthetic result. Free fat transfer can also provide moderate improvements in soft tissue volume, but long-term effects and durability are likewise not predictable. In addition to adding only volume, alloplastic implants also provide support for the ptotic soft tissue. This procedure renders an aesthetically desirable site-specific dimensional quality that also accounts for overall facial proportion.

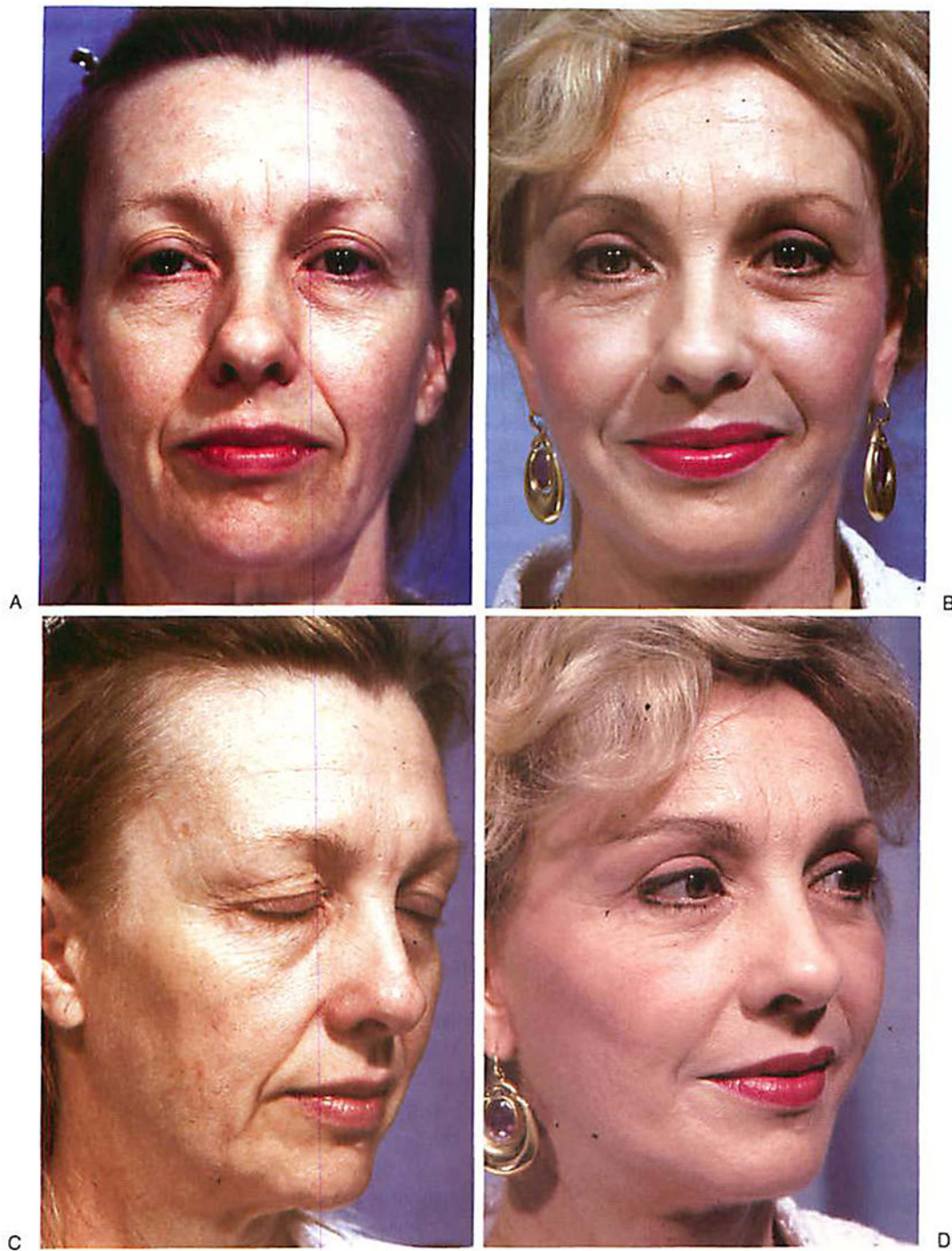Midface augmentation using alloplastic implants yields multiple advantages. Alloplastic augmentation provides a permanent, more durable option. Because alloplastic midface implants lie in the subperiosteal plane in tight proximity to the bone, they are not vulnerable to future soft tissue degradation.<sup>11</sup> Current alloplastic implant designs are available in a sufficient array of anatomic sizes and shapes, which are applicable to the majority of the population, and customized augmentation is also feasible (Fig. 4). Finally, midface augmentation using implants is reversible. The implants may be easily removed under local anesthesia or can be exchanged with minimal dissection. In particular, silicone implants, which become encapsulated after implantation, do not encourage tissue ingrowth and may be readily removed or replaced without tissue damage. Collectively, these benefits make midface augmentation an attractive option for midface volume enhancement.

#### THE PROCESS AND EFFECTS OF AGING IN THE FACE

The normal aging process begins between the third and fourth decades of life and rapidly accelerates through the fifth and sixth decades. Whereas abundant facial soft tissue, full cheeks, and smooth, pleasant contours typically connote youth,<sup>12</sup> loss of facial volume, descending soft tissue, and decreased skin elasticity are the hallmarks of aging in the face. With advancing age, fat in the malar, buccal, temporal, and infraorbital regions atrophies and produces volumetric changes in the face. Fat atrophy extends beyond the subcutaneous level and affects the deeper soft tissues along with the fat pad of Bichat. With continued wasting of the fat pads and loss of fascial support, these areas become progressively ptotic due to gravitational effects. The malar fat pad, suborbicularis oculi fat, and the orbicularis oculi muscle descend inferiorly, exaggerating the nasolabial folds and exposing the infraorbital rim. The nasolabial and nasojugal folds deepen leading to cavity depressions and hollowness in the submalar regions. These changes may initially flatten the midface and eventually unmask the underlying bony anatomy. Over time, the progressive, cumulative effects of aging transform the once full, angular, youthful face into a predictably rectangular (or pear-shaped) face, which appears longer in configuration, aged, and fatigued.

The majority of soft tissue deficiencies in the aging midface are located within the recess described





**Figure 3** (A, C) Preoperative views. (B, D) Postoperative result after submalar implants were concurrently placed with face-lift and upper and lower blepharoplasty.

as the "submalar triangle," an inverted triangular area of midfacial depression bordered superiorly by the prominence of the zygoma, medially by the nasolabial fold, and laterally by the body of the masseter muscle (Fig. 5).<sup>13</sup> Unlike the youthful midface, which presents as a single convexity in harmony with the lower eyelid aesthetics, the aging midface exhibits a "double convexity" curvature caused by weakening of the lower eyelid orbital septum and consequent pseudoherniation of the

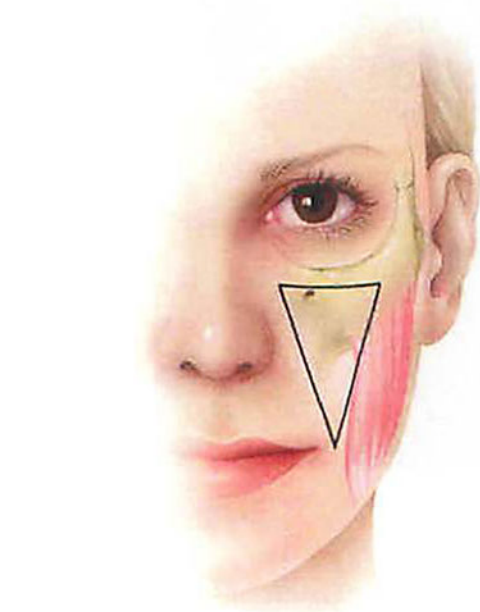
lower orbital fat pads.<sup>11</sup> Malar pads are typically voluminous and superiorly positioned in the youthful midface, but with advancing age and gravitational pull, they lose volume and descend lower into the face. Along with actinic and senescent skin changes, deterioration of the malar fat pads frequently renders a hollow or gaunt midface. Significant soft tissue involutional changes combined with deficient underlying bone structure further exaggerate the effects of the aging process.





**Figure 4** Example of a currently used midface implant that concentrates on providing midfacial volume. (Image courtesy of Implants Associates, Inc., Ventura, CA.)

Individuals who have thin skin lacking subcutaneous or deep supporting fat, but prominent cheekbones, may also exhibit depressions in the cheek area. The net sum of these topographical variations can make an otherwise healthy person appear gaunt. More severe forms of this pattern can also manifest in anorexia nervosa, starvation, or HIV-associated lipoatrophy. Protease inhibitors and other newer-generation HIV therapies also tend to erode the midfacial and buccal fat pads.<sup>14,15</sup> With the



**Figure 5** The inverted submalar triangle is an area of midfacial depression bordered medially by the nasolabial fold, superiorly by the malar eminence, and laterally by the main body of the masseter muscle. (From Binder WJ, Kim BP, Azizzadeh B. Aesthetic midface implants. In: Azizzadeh B, Murphy MR, Johnson CM, eds. *Master Techniques in Facial Rejuvenation*. Philadelphia, PA: Saunders; 2007:197–215. Reprinted with permission.)

combined aging effects, these conditions, which result in loss of facial volume, frequently preclude rhytidectomy or the use of fillers alone for long-term successful rejuvenation. Computer-assisted custom-designed facial implants have been permanently effective in these instances (Fig. 6).<sup>16</sup>

## MIDFACE REJUVENATION: GOALS AND APPROACHES

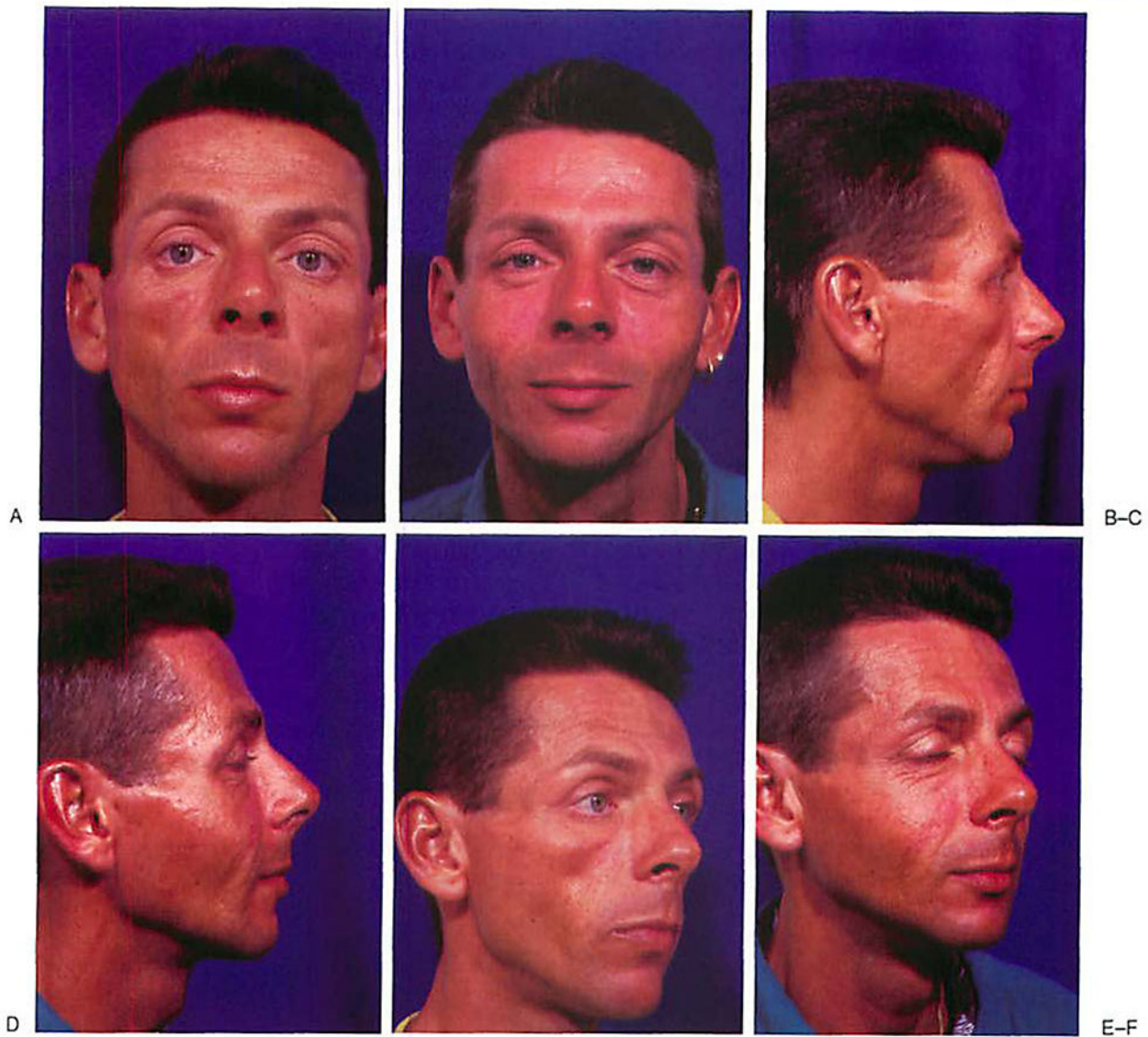The primary aim of facial augmentation using implants is to reconstruct facial contour deformities or deficiencies with normal skeletal contour utilizing a high degree of predictability. Specific goals for midface augmentation are to (1) add contour to the upper midface by restoring cheekbone fullness and reduce submalar hollows; (2) help transition the upper midface with a gradual slope to the lower face and neck; (3) soften the nasolabial and marionette folds; (4) reduce the vertical descent of the jaw; (5) smooth out facial lines and wrinkles. Midface implants may be used as an adjunct to face-lift procedures and can provide structural support in changing the shape of the face. In their ability to supply most of the deep volumetric change required, a foundation is also provided, which lessens the amount of soft tissue volumizers, such as fat or fillers, required to treat the more superficial and subcutaneous atrophic areas.

Because the pathophysiologic processes of aging are each isolated within the context of their anatomic components, such as the retaining ligaments, glide planes of the face, volumetric mass, bone, structure, and condition of the skin, midface rejuvenation should optimally proceed using a multilevel approach. This approach accounts for all elements composing the facial structure while aiming to correct, restore, and camouflage the descent and volume loss of the aging midface. Procedures addressing only one anatomic level or overuse of soft tissue volumizers may yield unfavorable results attempting to overcompensate for other procedures that might be better used. For example, relying on a soft tissue procedure in the absence of adequate bone structure may prove to be as faulty as depending on alloplastic support in patients with significant ptosis of the facial integument. Likewise, using filler or fat to correct a midfacial structural deficiency, such as a negative vector and malar and/or premaxillary deficiency, may be equally ineffective for ensuring long-term results.

## SURGICAL CONSIDERATIONS FOR MIDFACE ALLOPLASTIC IMPLANTS

Patients who exhibit prominent, well-balanced, and strong skeletal features generally withstand the negative effects of aging better than those lacking these attributes.<sup>17</sup> The ability to recognize structural and soft tissue defects and altered anatomy plays an integral role in





**Figure 6** (A, C, E) Preoperative view of a patient with midfacial wasting syndrome secondary to protease inhibitors for the treatment of HIV. (B, D, F) Postoperative photographs after the insertion of custom-designed midface implants. (From Binder W, Bloom D. The use of custom-designed midfacial and submalar implants in the treatment of facial wasting syndrome. *Arch Facial Plast Surg* 2004;6:395-397. Reprinted with permission.)

assessing a patient's eligibility for facial contouring procedures. Depending upon the underlying skeletal structure, however, involutional soft tissue changes become progressively pronounced and more obvious. Customizing the surgical plan for facial rejuvenation should consider all available options, including midface augmentation, face-lifts, and resurfacing techniques. Moderate midface rejuvenation involving placement of midface implants, as a sole procedure, may be suitable for middle-aged patients (ages 35 to 45 years) who exhibit early signs of facial aging but lack significant soft tissue laxity of jowls or deep neck rhytides (Fig. 2).<sup>3</sup> For patients requiring rhytidectomy due to significant facial laxity, alloplastic implants can recontour the midface and produce dramatic results unattainable by use of soft tissue techniques alone. For these patients, aug-

menting the bony scaffold of the malar region improves the fundamental base for suspension of the facial tissues. Patients with combined deficiencies of the facial skeleton and soft tissues or those who have a prominent malar skeleton but lack adequate submalar tissue may benefit particularly from this technique.

Technically, midface implant augmentation facilitates rhytidectomy by allowing the skin and soft tissue to be draped over a broader, more convex midface region. If placed prior to the rhytidectomy, midface implants can relieve traction on the perioral tissues, thereby eliminating the pull on the lateral commissures and avoiding the pulled or "overoperated" look. Similarly, subperiosteal dissection of the midface during implant placement releases the deep ligamentous attachments of the SMAS to the facial skeleton and

allows greater mobilization and suspension of ptotic soft tissues. This markedly enhances the results of sub-SMAS and deep plane rhytidectomy.<sup>6</sup>

### Preoperative Analysis and Implant Selection

A thorough understanding of the relative contributions of soft tissue and skeletal deficiencies in conjunction with accurate preoperative assessment can guide the surgeon in determining the optimal implant and placement and avoiding undesirable aesthetic results. The preoperative analysis for midface augmentation should also address the upper and lower face in conjunction with the midface. Preoperative photographs taken from the basal and apical bird's-eye view can aid in assessing the degree of midface volume loss and asymmetry and in the selection of appropriate implants. Although determining the appropriate implant fundamentally depends on the relationship between the bony prominences and the surrounding soft tissue, patterns of midface deformity can be generally grouped into three primary categories, each requiring a specific type of augmentation procedure and implant (Table 1). Prudent selection of the appropriate surgical procedure should include a separate evaluation of both the bony malar region and soft tissue submalar area. Sizers should be used to determine and confirm the appropriate implant size and shape.

The past decade has witnessed substantial improvements in implant form, design, and placement. Early cheek implants lacked anatomic form, and the historical placement of these prototypes high in the zygomatic malar complex often produced an unnatural "blocky" face with an exaggerated appearance.<sup>11</sup> Available in a variety of sizes and shapes, contemporary midface implants permit more conservative surgical approaches, which in turn provide a more targeted, precise, and natural-appearing augmentation tailored to different regions of the face. Advances in computer-assisted design/computer-assisted manufac-

turing technology have also facilitated fabrication of customized facial implants that can personalize the augmentation to the patient's or surgeon's preference while simultaneously correcting facial defects and asymmetries.

Typical implant materials include expanded polytetrafluoroethylene, methyl methacrylate, porous polyethylene, and silicone rubber. Polyethylene implants that promote tissue integration due to their porosity can be extremely difficult to remove or replace. Significant tissue injury and defects as well as implant fragmentation can occur with the removal of polyethylene implants. In contrast, the author prefers silicone implants, which are easily removed and/or replaced. Both have a low risk of infection.<sup>18-23</sup>

### Surgical Procedure for the Placement of Implants

Surgical insertion of midfacial implants is a simple, straightforward procedure, which can be performed by an experienced surgeon, usually in less than 30 minutes. The procedure can be accomplished using intravenous sedation or general anesthesia. Prior to insertion, the implants should be allowed to soak in an antibiotic solution (bacitracin 50,000 U/L). In the operating room, the surgeon should have access to a variety of implant sizes and shapes and must be ready and able to customize the implants should the need arise. Using a transoral approach, the implants are placed in the subperiosteal plane. This approach remains the standard because it facilitates insertion of the implant and direct visualization of all midface anatomic structures, including the infraorbital nerve.

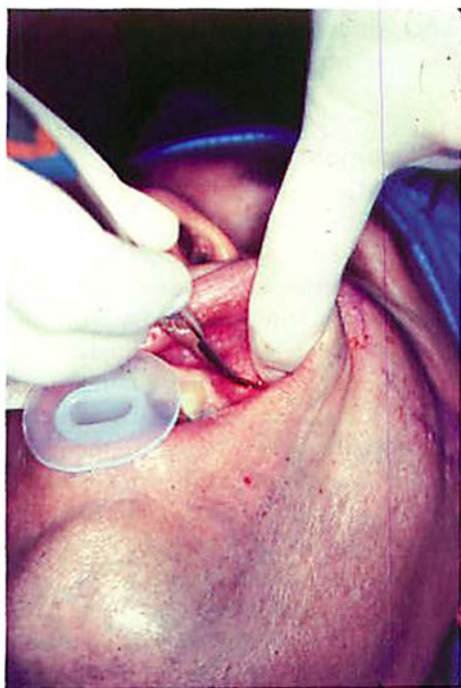### Incision and Dissection of the Malar Eminence

Incision and dissection of the malar eminence is initiated by making a 5-mm stab incision in the gingival-buccal sulcus over the lateral canine fossa

**Table 1 Patterns of Midface Deformity**

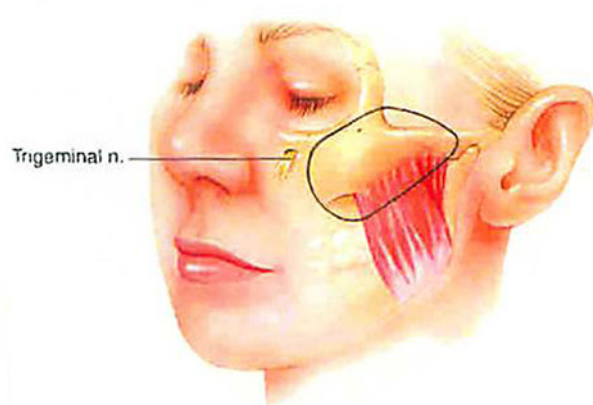
Deformity Type	Description of Midfacial Deformity	Type of Augmentation Required	Type of Implant Predominately Used
Type I	Primary malar hypoplasia; adequate submalar soft tissue development	Requires projection over the malar eminence	Malar implant: "shell-type" implant extends inferiorly into submalar space for more natural result
Type II	Submalar deficiency; adequate malar development	Requires anterior projection. Implant placed over face of maxilla and/or masseter tendon in submalar space. Also provides for midfacial fill.	Submalar implant (new conform type or generation I submalar implant)
Type III	Malar hypoplasia and submalar deficiency	Requires anterior and lateral projection; "volume replacement implant" for entire midface restructuring	"Combined" submalar-shell implant; lateral (malar) and anterior (submalar) projection. Fills large midfacial void.





**Figure 7** Oral incision for implant insertion. The gingival-buccal incision is made over the lateral canine fossa. Only 5 mm is required for the initial incision because the mucosa will stretch and provide adequate exposure of the midface skeleton. A 1- to 1.5-cm cuff of gingival mucosa is maintained inferiorly. (From Binder WJ, Kim BP, Azizzadeh B. Aesthetic midface implants. In: Azizzadeh B, Murphy MR, Johnson CM, eds. *Master Techniques in Facial Rejuvenation*. Philadelphia, PA: Saunders; 2007:197–215. Reprinted with permission.)

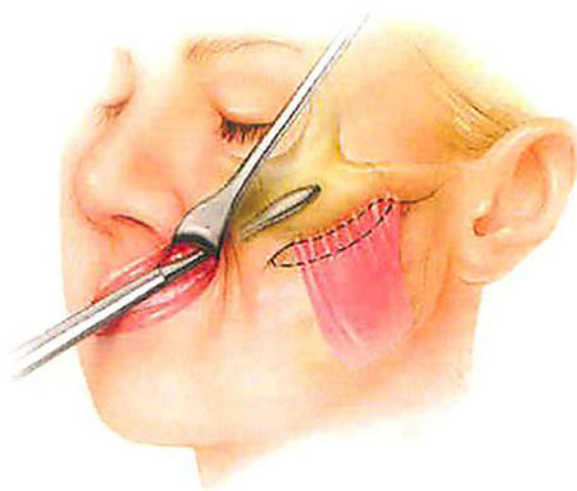and maxillary buttress (Fig. 7). It is not necessary to dissect medially to the pyriform aperture, as no part of the implant lies within this region.<sup>11</sup> Following an upward oblique direction, the incision is carried immediately and directly onto the maxillary bone. Leaving a cuff of gingival mucosal measuring at least 1-cm wide facilitates closure at the end of the procedure. The periosteum of the anterior maxilla is elevated superiorly and laterally. Using the preoperative markings, the surgeon's external free hand plays a critical role in guiding the direction and extent of dissection. Meticulous care should be exercised in avoiding extensive dissection, stretching, and traction around the infraorbital foramen. The infraorbital nerve is carefully identified to avoid placement of the implant over the foramen in the event that the proposed implant is large or has a significant medial component. Dissection is then extended laterally to the malar-zygomatic junction and zygomatic arch. The subperiosteal plane is used for dissection particularly over the lateral zygomatic arch where branches of the facial nerve traverse just superficial to this plane. Gentle blunt dissection over the midzygomatic arch will assist in preventing injury to the temporal branch of the facial nerve (Fig. 8).



**Figure 8** The initial dissection occurs over the anterior maxillary wall, zygoma, and zygomatic arch. (From Binder WJ, Kim BP, Azizzadeh B. Aesthetic midface implants. In: Azizzadeh B, Murphy MR, Johnson CM, eds. *Master Techniques in Facial Rejuvenation*. Philadelphia, PA: Saunders; 2007:197–215. Reprinted with permission.)

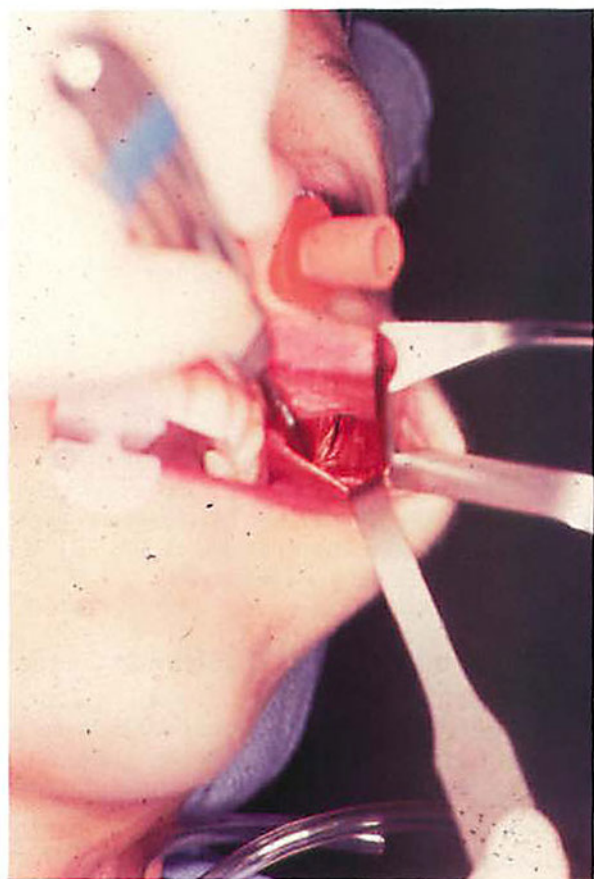
### Exposure of the Submalar Triangle and Creation of the Implant Pocket

Patients with types II and III midface deficiencies require exposure of the submalar space, which is accomplished by extending the subperiosteal dissection inferiorly below the zygoma and over the superior tendinous origin of the masseter muscle (Fig. 9). By gently elevating the overlying soft tissue from the deeper plane of the tendon, the surgeon can visualize the glistening white tendinous attachment of the masseter (Fig. 10). Here, the muscle attachments are not divided because they serve as a crucial platform for the lateral portion of the submalar implant. Posteriorly, the



**Figure 9** The area between the dashed lines represents the submalar dissection over the masseteric tendon. (From Binder WJ, Kim BP, Azizzadeh B. Aesthetic midface implants. In: Azizzadeh B, Murphy MR, Johnson CM, eds. *Master Techniques in Facial Rejuvenation*. Philadelphia, PA: Saunders; 2007:197–215. Reprinted with permission.)





**Figure 10** The inferior aspect of the dissection in the submalar space is over the masseteric tendon and inferior to the lateral zygomatic arch. In this region, the soft tissues are gently elevated exposing the glistening white fibers of the masseteric tendon. Note the tendon is exposed but is not cut.

submalar space becomes much narrower and is not easily accessed. The surgeon can carefully dissect the posterior limit by advancing a blunt elevator along the inferior zygomatic arch which will prevent displacement of the implant postoperatively. A pocket is created over the malar-zygomatic complex and submalar triangle that is large enough to accommodate the appropriate implant. Because an implant that is forced into an ill-fitted pocket will become displaced, the final dissected space should be larger than the actual implant and allow placement without compression by the surrounding tissues, particularly in the posterior region. Migration or extrusion of the implant can also occur due to inadequate exposure and constriction of the posterolateral portion of the pocket, which pushes the implant anteriorly. As a rule, the surgeon should be able to move the implant at least 3 to 5 mm in all directions. Customized anatomic implants frequently seek the proper position, but caution must be exercised to prevent the thin implant tail from folding over on itself. The periosteum and soft tissues generally reapproximate imme-

diately after surgery and obliterate the dead space within 24 to 48 hours.<sup>24</sup>

### Implant Placement

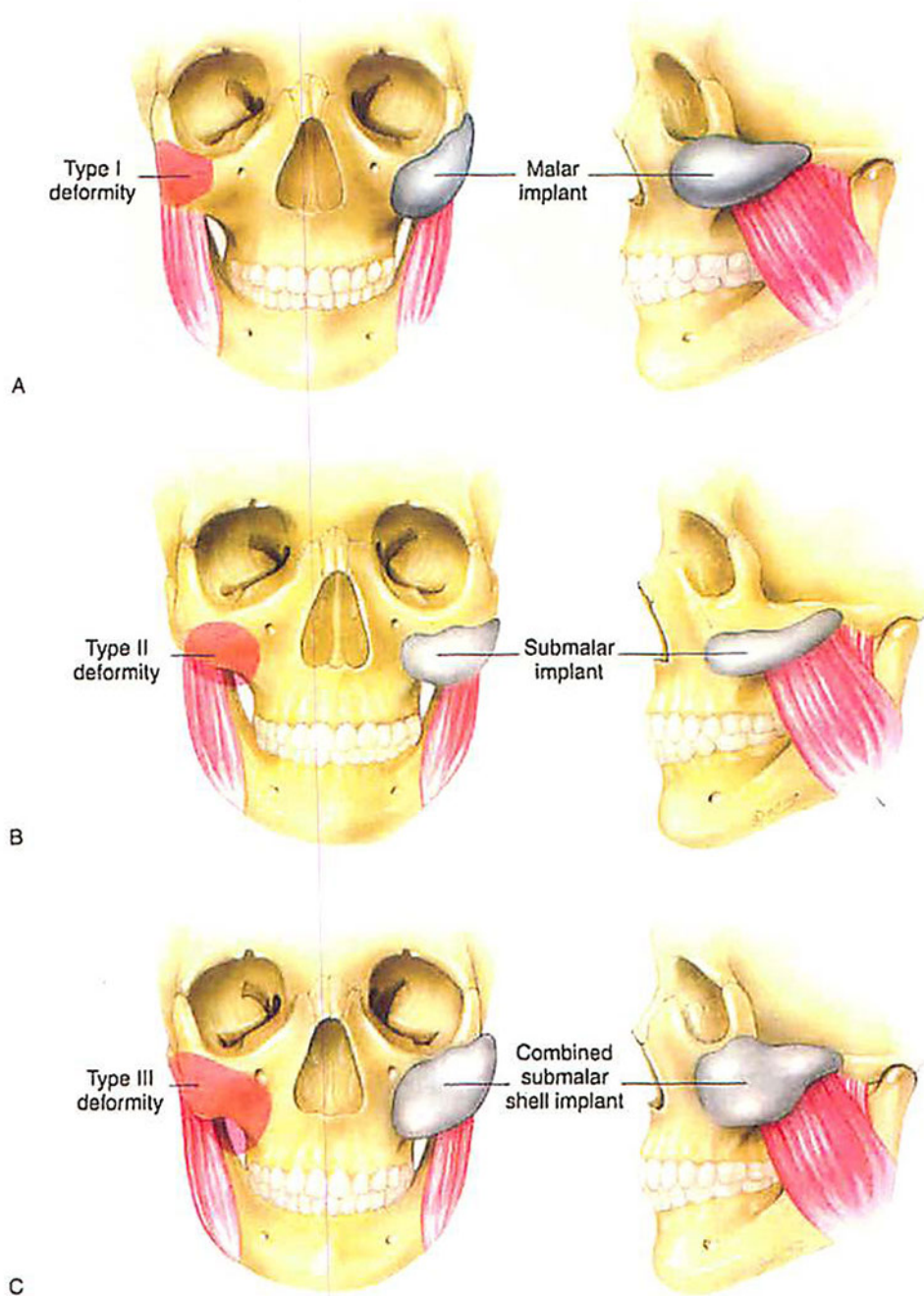
The precise location of the midfacial implants is dictated by the results of the preoperative facial analysis, type of deformity, and the patient's desires. For patients with type I deformity, malar shell implants rest on top of the malar and zygomatic bone in a more superior and lateral position (Fig. 11), whereas submalar implants for type II deformity generally lie over the anterior face of the maxilla. Combined malar-submalar implants for type III deformity will cover both the malar bony eminence and the submalar triangle. Positioning an implant in the submalar triangle requires more subjectivity than placement over the malar eminence and generally necessitates keen judgment to achieve the desired changes in facial contour.

After inserting the implants, the surgeon should assess for facial asymmetry using a ruler to measure the distances from the medial border of the implants to the midline. Standing at the head of the table generally aids in assessing for contour symmetry. Asymmetry may be particularly evident in patients who have thin skin or prominent facial skeleton. In these cases, the edges and contours of larger, thicker implants tend to be palpable with visible irregularities if not addressed during the initial procedure. Correcting preexisting facial asymmetry can be very challenging, necessitating exquisite attention to the bony and soft tissue topography. In these instances, a surgeon may need to asymmetrically contour and position each implant.

### Securing the Implant

Well-conforming and the newer larger midface implants are not prone to migration and usually do not require fixation. However, midface implants may be secured using either of two external suture fixation techniques. In applying indirect lateral suture fixation, the surgeon passes long (10-inch) double-armed Keith needles on 3-0 silk suture through the lateral end of the implant. The needles are then placed into the wound and are directed posterolaterally, exiting the temporal region behind the hairline. The implant is situated in its final position, and the sutures are tied over a cotton roll bolster. This method is well suited for malar shell implants (type I deformity) because it exerts superolateral tension on the implants and thereby maintains their position over the bony malar-zygomatic eminence. An alternative direct external fixation technique is more appropriate for securing submalar and more inferiorly placed malar-submalar facial implants (type II and III deformities) and is also the preferred method for securing implants





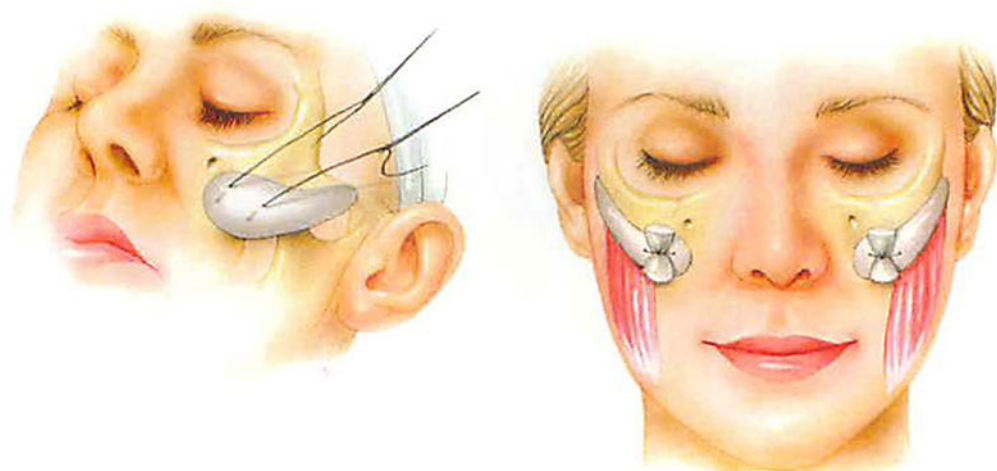
**Figure 11** Implant placement. (A) Malar shell implants for type I deformity rest on top of the malar and zygomatic bone in a more superior and lateral position. (B) Submalar implants for type II deformity lay over the anterior face of the maxilla. (C) Combined malar-submalar implants for type III deformity cover both the malar bony eminence and the submalar triangle. (From Binder WJ, Kim BP, Azizzadeh B. *Aesthetic midface implants*. In: Azizzadeh B, Murphy MR, Johnson CM, eds. *Master Techniques in Facial Rejuvenation*. Philadelphia, PA: Saunders; 2007:197–215. Reprinted with permission.)

exhibiting excessive mobility within the wound pocket (Fig. 12).

Midface implants usually have two preformed fenestrations. If no fenestrations are present, the author uses a 2-mm punch biopsy instrument to make the holes in the implant. The position of the medial fenestration should be marked on the external skin while the implant is inside the subperiosteal pocket. The surgeon can

confirm symmetry by measuring and comparing the distance of each marking to the midline. After marking the medial fenestrations, the implants are removed and placed on top of the midface. The implants are positioned to coincide with the desired contour and preoperative markings; the skin is marked a second time at the area coinciding with the location of the lateral fenestration of the implant. The surgeon passes double-armed





**Figures 12** (A, B) Direct fixation of the implant. The double-armed suture is passed through the implant and externally out through the skin. It is tied over a bolster composed of two dental rolls. It is secured there and the suture cut and removed, along with the bolster, the next postoperative day. (From Binder WJ, Kim BP, Azizzadeh B. Aesthetic midface implants. In: Azizzadeh B, Murphy MR, Johnson CM, eds. *Master Techniques in Facial Rejuvenation*. Philadelphia, PA: Saunders; 2007:197–215. Reprinted with permission.)

3–0 silk sutures through the medial and lateral fenestrations with the loop around the deep surface of the implant. The needles are then placed into the wound pocket and passed perpendicularly through the skin markings corresponding with each fenestration. The implant is then inserted into the pocket, ensuring proper position and symmetry. The sutures are gently tied over cotton roll bolsters overlying the anterior cheek. This also helps to compress the midface, reduce any potential dead space, and prevent fluid from collecting in the subperiosteal pockets. External sutures and bolsters are removed the next day.

Implants placed prior to a concurrent rhytidectomy procedure may be secured with internal suture fixation. If external suture fixation is preferred, the implant should be left in place with the oral incision temporarily or loosely closed. When the rhytidectomy is completed, the surgeon can reopen the oral incision to reposition and fix the implant with external sutures. If necessary, intraoral Penrose drains can be placed.

### Postoperative Care

Patients may recover either at home or in an aftercare facility. Antibiotics, analgesics, and antiemetics are routinely prescribed, and patients are advised to apply ice packs for 3 to 4 days and to sleep with the head elevated. The initial postoperative visit typically occurs on the first or second day, at which time facial dressings, external sutures, and any intraoperative drains are removed. Patients are followed regularly thereafter until resolution of facial edema. Most patients resume routine activity as early as 5 to 7 days postoperatively.

### Potential Complications

Significant postoperative edema is not uncommon. Approximately 80 to 85% of edema resolves within 3 to 4 weeks; the remaining 15 to 20% gradually subsides over the ensuing 6 months.<sup>3</sup> Malpositioning of the implant may result from incorrect placement, insufficient pocket size, or inadequate fixation of the implant. Implant extrusion should not occur if proper technique is followed. Other complications include bleeding, hematoma, seroma, fistula, pain, and persistent inflammatory action. Approximately 1% of patients receiving alloplastic silicone implants develop postoperative infections.<sup>25</sup> Infraorbital and facial nerve injury may also occur but is rarely permanent.

### CONCLUSION

Facial augmentation and volume restoration using alloplastic implants provides excellent long-term solutions and advantages for correcting underlying skeletal abnormalities, loss of soft tissue volume, and contour irregularities prevalent in the aging face. Because of the ability to address multiple anatomic deficiencies and allow for customization and greater precision in correcting facial defects, use of alloplastic implants will maintain a necessary and prominent role in facial aesthetic surgery.

### REFERENCES

1. Matros E, Momoh A, Yaremchuk MJ. The aging midfacial skeleton: implications for rejuvenation and reconstruction using implants. *Facial Plast Surg* 2009; 25:252–259



2. Binder W, Kim B, Azizzadeh B. Aesthetic midface implants. In: Azizzadeh B, Murphy M, Johnson C, eds. *Master Techniques in Facial Rejuvenation*. Philadelphia, PA: Saunders-Elsevier Medical Publishers; 2006:197-215
3. Hopping SB, Joshi AS, Tanna N, Janjanin S. Volumetric facelift: evaluation of rhytidectomy with alloplastic augmentation. *Ann Otol Rhinol Laryngol* 2010;119:174-180
4. Quatela VC, Marotta JC. Pitfalls of midface surgery. *Facial Plast Surg Clin North Am* 2005;13:401-409
5. Psillakis JM, Rumley TO, Camargos A. Subperiosteal approach as an improved concept for correction of the aging face. *Plast Reconstr Surg* 1988;82:383-394
6. Tessier P. [Subperiosteal face-lift]. *Ann Chir Plast Esthet* 1989;34:193-197
7. Ramirez OM. The subperiosteal rhytidectomy: the third-generation face-lift. *Ann Plast Surg* 1992;28:218-232; discussion 233-234
8. Hamra ST. The deep-plane rhytidectomy. *Plast Reconstr Surg* 1990;86:53-61; discussion 62-63
9. Kemer FM. One hundred consecutive deep plane face-lifts. *Arch Otolaryngol Head Neck Surg* 1996;122:17-22
10. Chajchir A, Benzaquen I. Liposuction fat grafts in face wrinkles and hemifacial atrophy. *Aesthetic Plast Surg* 1986;10:115-117
11. Niamtu J III. Essentials of cheek and midface implants. *J Oral Maxillofac Surg* 2010;68:1420-1429
12. Broadbent TR, Mathews VL. Artistic relationships in surface anatomy of the face: application to reconstructive surgery. *Plast Reconstr Surg* (1946) 1957;20:1-17
13. Flowers RS. Cosmetic blepharoplasty, state of the art. In: *Advances in Plastic and Reconstructive Surgery*. Vol. 8. St. Louis, MO: Mosby Year Book Inc.; 1992:31
14. Carr A, Samaras K, Burton S, et al. A syndrome of peripheral lipodystrophy, hyperlipidaemia and insulin resistance in patients receiving HIV protease inhibitors. *AIDS* 1998;12:F51-F58
15. Kotler DP, Rosenbaum K, Wang J, Pierson RN. Studies of body composition and fat distribution in HIV-infected and control subjects. *J Acquir Immune Defic Syndr Hum Retrovirol* 1999;20:228-237
16. Binder WJ, Bloom DC. The use of custom-designed midfacial and submalar implants in the treatment of facial wasting syndrome. *Arch Facial Plast Surg* 2004;6:394-397
17. Romm S. Art, love, and facial beauty. *Clin Plast Surg* 1987;14:579-583
18. Wilkinson TS. Complications in aesthetic malar augmentation. *Plast Reconstr Surg* 1983;71:643-649
19. Silver WE. The use of alloplast material in contouring the face. *Facial Plast Surg* 1986;3:81-98
20. Whitaker LA. Aesthetic augmentation of the malar-midface structures. *Plast Reconstr Surg* 1987;80:337-346
21. Prendergast M, Schoenrock LD. Malar augmentation. Patient classification and placement. *Arch Otolaryngol Head Neck Surg* 1989;115:964-969
22. Binder WJ. Submalar augmentation. An alternative to face-lift surgery. *Arch Otolaryngol Head Neck Surg* 1989;115:797-801
23. Terino EO. Alloplastic facial contouring by zonal principles of skeletal anatomy. *Clin Plast Surg* 1992;19:487-510
24. Binder WJ. A comprehensive approach for aesthetic contouring of the midface in rhytidectomy. *Facial Plast Surg Clin North Am* 1993;1:231-255
25. Rubin JP, Yaremchuk MJ. Complications and toxicities of implantable biomaterials used in facial reconstructive and aesthetic surgery: a comprehensive review of the literature. *Plast Reconstr Surg* 1997;100:1336-1353