

Considerations in Non-Caucasian Facial Plastic Surgery

GUEST EDITOR

Samuel M. Lam, MD, FACS

FACIAL PLASTIC SURGERY CLINICS OF NORTH AMERICA



February 2010 • Volume 18 • Number 1

Midface Alloplastic Augmentation in the Asian and Latino Patient

A. Joshua Zimm, MD^{a,b}
William J. Binder, MD^{c,d,e,*}

KEYWORDS

- Midface augmentation • Alloplastic augmentation
- Asian facial cosmetic surgery
- Latino facial cosmetic surgery

In recent years, the population of the United States has become more diverse as there is an ever expanding influx of various ethnic groups and races that comprise the general population. According to the US Census Bureau, the nation will be more racially and ethnically diverse, as well as older, by 2050. The non-Caucasian population is projected to be 235.7 million out of a total United States population of 439 million by mid century. Today, Asians make up 5% (15.3 million) of the United States population. This figure is expected to nearly double to 9% (39.5 million) by 2050. The Latino, or Mestizo population now comprises 15% of the population of the United States (45.9 million). By 2050, it is expected to increase to 30% of the population (131.7 million).¹ As a result, the singular concept of Nordic beauty that dominated the United States media throughout the middle of the twentieth century has given way to a more diverse multiracial aesthetic, as championed in the entertainment industry, with the choice of multicultural fashion models that grace the runways and print media.² In addition, there is a growing trend in aesthetic surgery toward

ethnic feature preservation and avoidance of a “westernized” look that was more popular in previous years. Today’s facial plastic surgeon must be familiar with these trends and aesthetic goals within this rapidly growing patient population. This article describes the anatomy of the Asian and Latino face and describes the techniques of midface alloplastic augmentation.

There are various facial characteristics that present unique challenges in the Asian patient. A review of these characteristics will prove helpful to frame this discussion. Asian skin is thicker and contains greater collagen and pigmentation. The Asian face is also subjected to different gravitational and directional forces due to an overall wider midfacial skeletal structure, increased malar fat, and a weaker chin.³ The midface in Asian patients is typified by dense fat both superficial and deep to the superficial musculoaponeurotic system (SMAS). The combination of increased superficial fat and a thicker dermis lessens the incidence of superficial rhytids in Asian patients. The fat and fibrous connections between the SMAS and parotidomasseteric fascia decrease the amount of soft tissue ptosis in

^a 1421 Third Avenue, 4th Floor, New York, NY 10028, USA

^b Department of Otolaryngology-Head and Neck Surgery, Manhattan Eye, Ear, and Throat/Lenox Hill Hospital, 210 East 64th Street, 3rd floor, New York, NY 10065, USA

^c Facial Plastic and Reconstructive Surgery, 120 South Spalding Drive, Suite 340, Beverly Hills, CA 90212, USA

^d Department of Head and Neck Surgery, UCLA School of Medicine, Los Angeles, CA, USA

^e Department of Head and Neck Surgery, Cedars Sinai Medical Center, Los Angeles, CA, USA

* Corresponding author. Facial Plastic and Reconstructive Surgery, 120 South Spalding Drive, Suite 340, Beverly Hills, CA 90212.

E-mail address: wjbmd8@aol.com (W.J. Binder).

many Asians. For these reasons, the midface in Asians usually has minimal rhytids and a mild to moderate amount of ptosis as the patient ages. However, because of the dense attachments between the fascial layers, soft tissue surgical rejuvenation procedures usually do not provide as much soft tissue elevation in Asian patients.⁴

The typical facial skeleton in Asians has a strong and wide zygomaticomalar region. The bizygomatic width of these patients measures above average. The lower facial skeleton is often characterized by a weak chin in the anterior-posterior dimension, but the bimaxillary width is usually wider in Asians than in Caucasians. In addition, the anterior-posterior distance between the mentum and hyoid bone is typically shorter than in Caucasians. Chin augmentation accordingly is often a useful adjunct to facial rejuvenation surgery in this population (**Fig. 1**). The dental occlusion in Asians can have mild to moderate bimaxillary protrusion that causes the lower lip to be slightly protuberant, which often accentuates and exaggerates their microgenia. The position of the lower lip should therefore not be used as the only factor in judging ideal chin position. Chin augmentation should be performed conservatively, leaving the lower lip slightly protruding to maintain the ethnicity of the Asian face.⁴

Skin incisions in Asians have a greater propensity toward hypertrophic and keloid scars, tend to remain erythematous for a longer period of time, turn hyperpigmented for an unacceptable length of time, or remain hypopigmented.⁵ Also, the Asian face tends to be wider and less angular than the Caucasian, similar to a toddler. Except for a portion of the Korean population, the midface tends to be shallower due in part to hypoplasia of the malar bone, with a lower nasal dorsum, fuller eyelids, and a more superficial orientation of the orbital rim. Cultural factors are important in this analysis as well. Prominent malar eminences, or "high cheek bones," which are a celebrated feature of Caucasian women, are often construed as an unfavorable trait in this population. The excessively high malar eminences, found particularly in Koreans, are often considered masculine features and deemed unattractive within their culture.³

Latinos, or Mestizos, who represent a mixture of European immigrants and the native populations of the Americas, have a strong mongoloid component in their facial features, and therefore have similar characteristics to Asians. Facial features of this ethnic group include thick sebaceous skin, abundant malar fat, prominent malar eminences, upper eyelid hooding, a broad face, a wide nasal dorsum, a platyrrhine or mesorrhine nose, a wide bigonial angle, and a protrusion of the dental arches that project the upper lip anteriorly resulting in an acute

nasolabial angle.^{6,7} It should be noted that these are rough generalizations regarding the various races and ethnic groups. Given the extensive interracial mingling in our society, there are various subpopulations within these broad categories.

The use of facial implants began in the 1950s with various primitive cheek and chin implants. Since then, there have been advances in materials, shapes of implants, surgical techniques and, perhaps most importantly, the understanding of the role of volume and skeletal structure in the aging process. The facial skeleton and its corresponding soft tissue form the architecture of the face and neck. Facial implants augment the soft tissue and skeletal framework by replacing volume lost during the aging process, supporting soft tissue and elevating it to a more youthful position.⁸ Binder's innovations in the 1980s established midface augmentation with malar/submalar implants as an independent and powerful method for midface rejuvenation by helping restore lost midfacial volume.⁹

During the aging process, there are several characteristic changes in the midface. There is a loss of skin elasticity, soft tissue volume depletion, descent of soft tissue, and a diminution of the dental and skeletal support of the soft tissue envelope.⁴ As the malar, buccal, temporal, and infraorbital fat pads atrophy and lose their facial support, these areas become progressively ptotic secondary to gravity. The nasolabial folds become exaggerated, and the infraorbital rim becomes exposed. In conjunction with deepening of the nasolabial and nasojugal folds, submalar hollowness and cavitory depressions occur. These changes initially flatten the midface, which leads to exposure of the underlying bony anatomy creating an aged, fatigued appearance. By elevating, supporting, and replacing lost midface volume, midface implant techniques underscore the notion that the face can be rejuvenated successfully not only via "lifting" procedures but also through the augmentation of the soft tissue and skeletal foundation.^{9,10} Alloplastic midface augmentation is especially helpful in the Asian and Latino populations, who as a result of the aging process acquire more significant flattening of the midface, and thus become an ideal group for anterior projection and support of the premaxillary and submalar area.

From a technical point of view, midface augmentation using alloplastic implants is straightforward and bears relatively few risks. The implantation is reversible and may be combined with standard rhytidectomy techniques. The aesthetic benefit is consistent, predictable, and lasting. Midface implants can replace lost volume, reduce midface laxity, and decrease the depth of the nasolabial folds (**Fig. 2**). Submalar

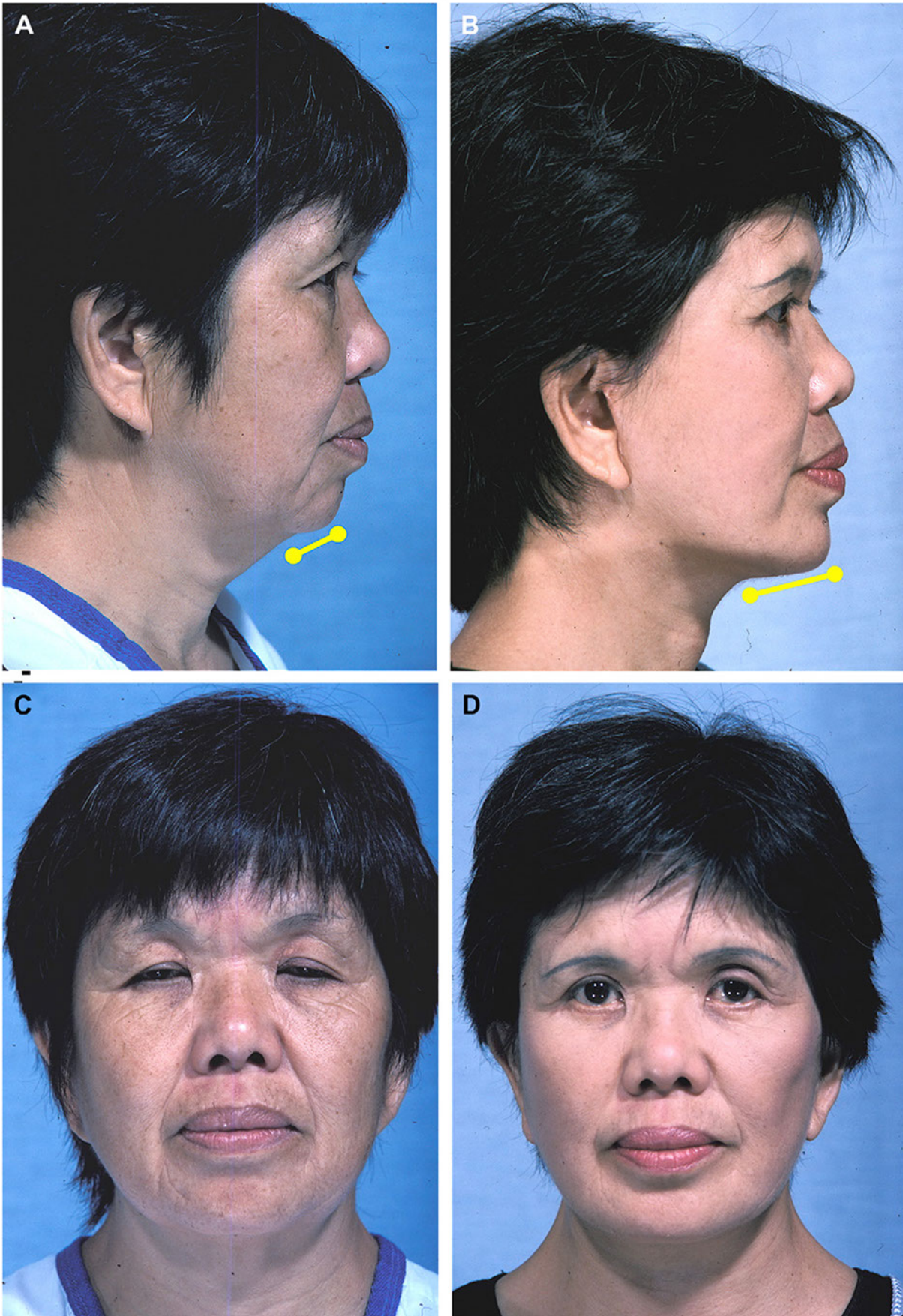

Fig. 1. Asian chin augmentation. (A, C) Preoperative photographs of an Asian patient with microgenia and a shortened distance between the mentum and hyoid bone, who underwent a rhytidectomy, chin implant, upper and lower lid blepharoplasty, and perioral dermabrasion. (B, D) Postoperative photographs showing improved mandibular projection and lower facial harmony.

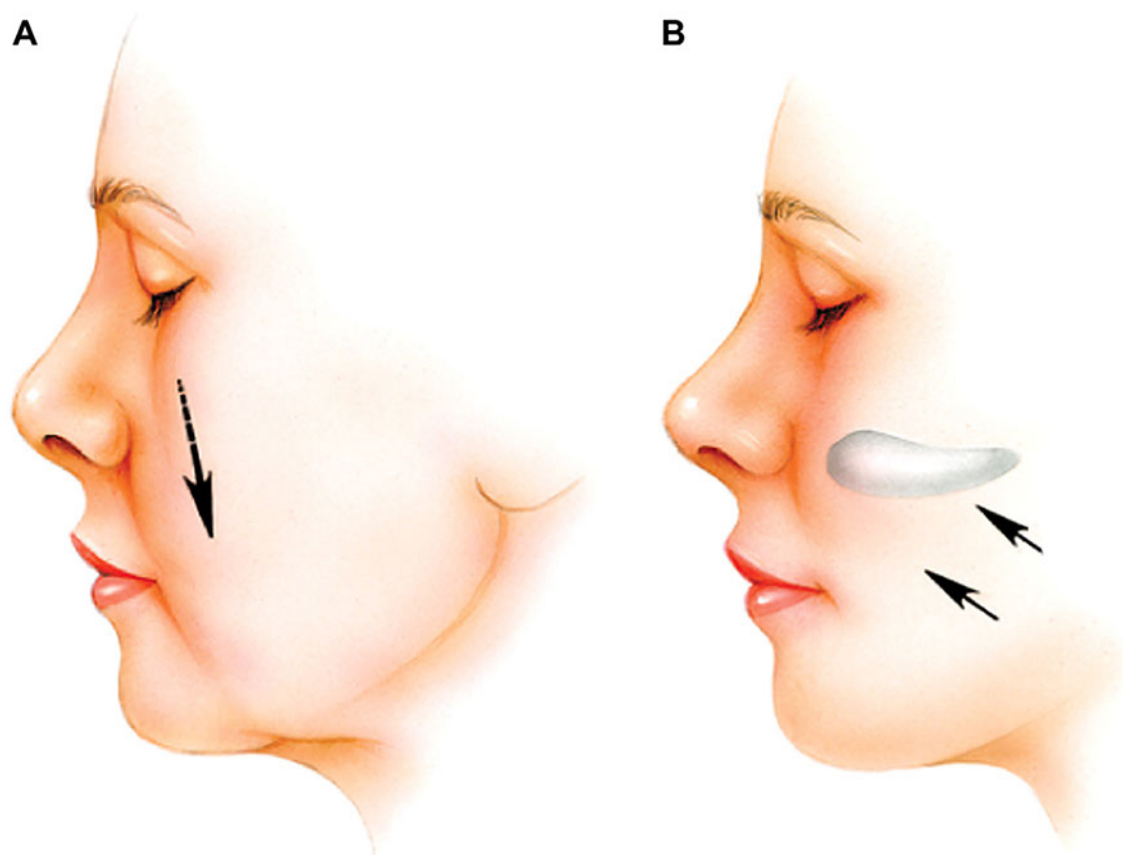


Fig. 2. (A, B) Suspension effect of midface implants. Midface implants augment the facial skeleton and restore soft tissue volume. The combined effect is to relocate the malar prominence to a more anterosuperior location and restore the hollow regions. (From Binder WJ, Azizzadeh B. Aesthetic midface implants. In: Azizzadeh B, Murphy MR, Johnson CM, editors. Master techniques in facial rejuvenation. Philadelphia: Saunders; 2007. p. 197–215; with permission.)

augmentation, performed in isolation, can provide a moderate amount of midfacial rejuvenation in middle-aged patients (age 35 to 45 years) who show early signs of facial aging and atrophy but lack the soft tissue laxity of extensive jowling or deep neck rhytids.⁹

When combined with rhytidectomy, midface alloplastic augmentation can either sharpen or soften angles and depressions of the aging face, which can lead to a more natural look. The implants allow the skin and soft tissue to be draped over a broader, well-defined area after midface augmentation of the bony scaffold (**Fig. 3**). In addition, if placed before facelifting, midface implants reduce lateral traction forces on the oral commissure, which also prevents an unnatural “overoperated” appearance. Finally, undermining of the midface periosteum during implant placement releases the deep attachments of the SMAS to the facial skeleton, thereby allowing greater mobilization and suspension of the ptotic soft tissues. The implant therefore acts as a spacer and prevents rapid reattachment of the periosteum, which keeps the midfacial soft tissues in an elevated and augmented position. As

a result, midface alloplastic augmentation can significantly enhance and prolong the cosmetic outcomes of subperiosteal, sub-SMAS, and deep plane rhytidectomy (**Fig. 4**).^{9,11}

Midface augmentation can thus achieve dramatic aesthetic results not achievable through soft tissue suspension techniques alone. Furthermore, many patients with prominent malar skeletons (as in the Asian population) but inadequate submalar soft tissue will benefit from volumetric enhancement of the midface inferior to the prominent zygomatic process. Also, patients having midface augmentation with concomitant revision rhytidectomy will benefit from having decreased downward vertical forces on the lower eyelid. Other procedures such as deep plane facelifting and subperiosteal facelifting can provide viable alternatives to midface alloplasts; however, if problems with volume loss and loss of facial shape are not addressed, the face may appear skeletonized, especially in those with very prominent bone structure and thin skin.⁹

Injectable soft tissue fillers and fat transfer offer another option for improving midfacial aesthetics.

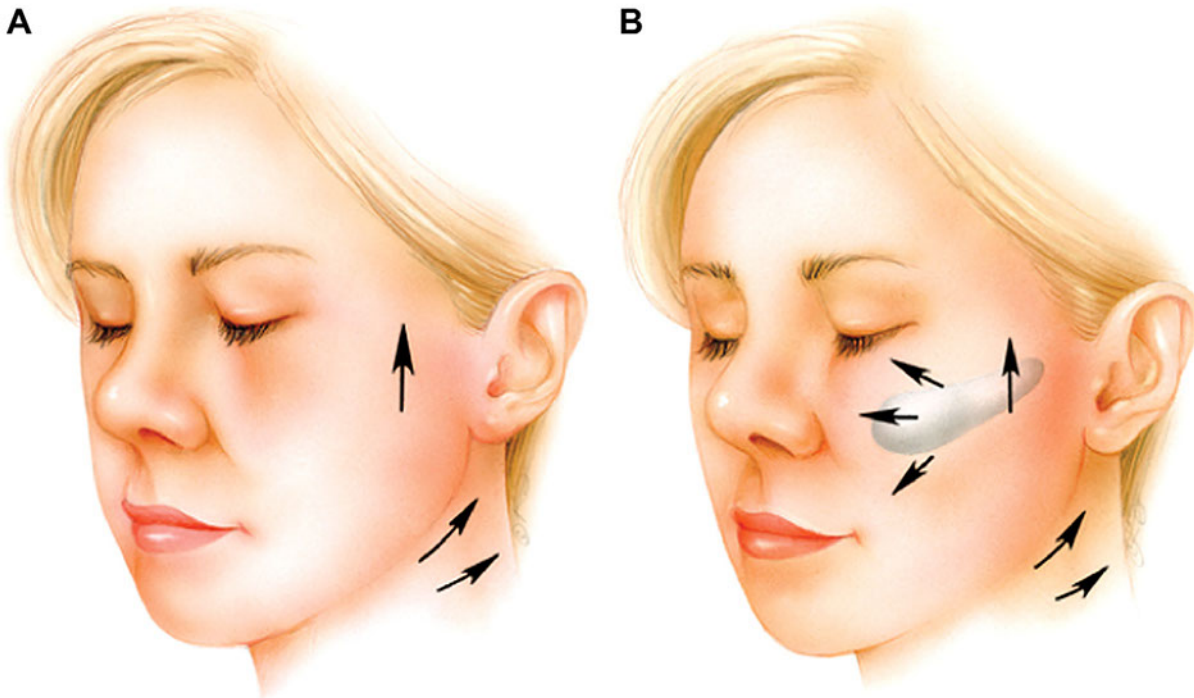


Fig. 3. Convexity effect of midface implants. (A) Facelifts generally stretch skin over a flat midface structure in a 2-dimensional pattern. (B) Malar and submalar implants augment the bony and soft tissues of a more convex midface region that allows a more natural draping, resulting in a third dimension for facial rejuvenation. (From Binder WJ, Kim BP, Azizzadeh B. Aesthetic midface implants. In: Azizzadeh B, Murphy MR, Johnson CM, editors. Master techniques in facial rejuvenation. Philadelphia: Saunders; 2007. p. 197–215; with permission.)

However, the most important difference between fillers and midfacial implants is that implants not only provide support and volume to ptotic soft tissue, they also allow for a fixed 3-dimensional quality to the face and support of the soft tissues that volumetric filling alone cannot achieve. Fillers in the midface in large amounts can migrate laterally and result in an amorphous, overfilled, and unnatural look.⁹

A key anatomic region in the midface is the submalar triangle, which is bordered superiorly by the zygomatic prominence, medially by the nasolabial fold, and laterally by the masseter muscle. This anatomic area represents the most common site of volume loss in the aging midface, especially in Asians and Latinos, but can be corrected readily with alloplastic implants (**Fig. 5**).

PREOPERATIVE ANALYSIS

Preparing for midfacial alloplastic augmentation begins with a thorough history and physical examination followed by digital photographs and optional digital computer imaging. The computer imaging can help the patient identify the exact nature of their concerns and potential benefits of surgery. It is also important to analyze the entire upper and lower face and neck. Basal photos

and apical bird's eye views are especially helpful in identifying midface pathology and can help in selecting midface implants. Preoperative analysis and discussion of soft tissue and skeletal asymmetries is imperative both to prevent exaggeration of these effects postoperatively and to avoid unrealistic patient expectations.⁹

Selecting the appropriate midfacial implant requires an ability to recognize the characteristics of midface deformity (**Table 1**).^{10,12} Ideal evaluation requires separate analyses of the bony malar area and the soft tissue component of the submalar region. Patients exhibiting type I deformity with primary malar hypoplasia and adequate midface soft tissue are best suited for malar shell implants that cover the zygoma and contiguous areas. These implants yield an arched appearance and project the cheek laterally. Fine edges gradually blend into the adjacent tissues to avoid abrupt changes in the facial architecture.

The most common deformity of the aging face, especially in Asians and Latinos, is a type II submalar deficiency. This deformity is characterized by normal malar skeletal structure and soft tissue atrophy of the midface. Volume loss and inferior descent of the midface soft tissues leaves an excavated, flattened appearance. Submalar implants are the implants of choice for patients with this deformity.

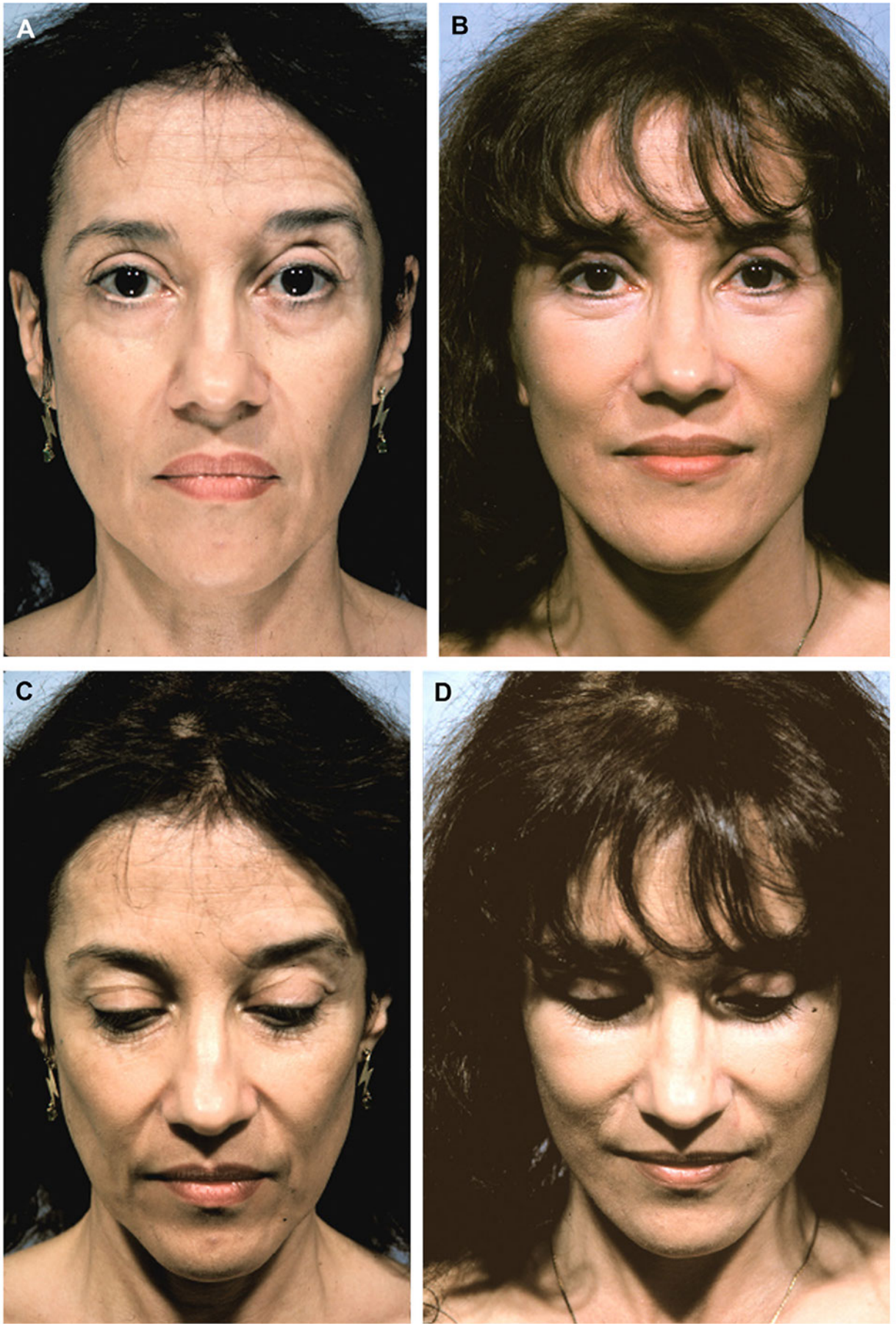

Fig. 4. Rhytidectomy and submalar implants. Preoperative photos (A, C, E) in a Latino woman with good midfacial bone structure. The malar eminence is relatively high and sharp adding to the contrast within the submalar region. This patient achieved a significant and long-term benefit from the submalar implant, which can be seen to elevate and support the midface in the postoperative photos (B, D, F).

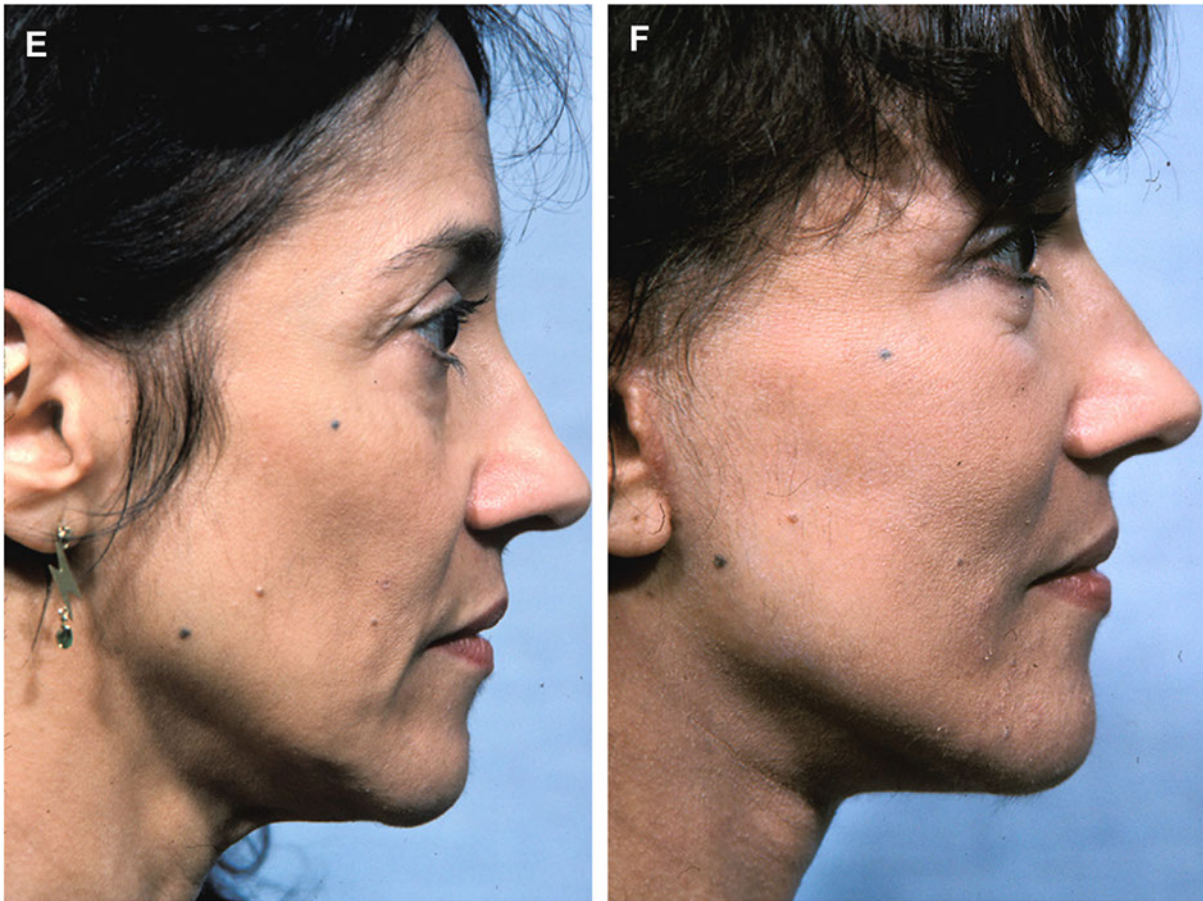

Fig. 4. (continued) (E) Preoperative side view. (F) Postoperative side view.

Type III deficiency is characterized by both a malar and submalar deficiency. The effects of aging are exaggerated in these patients, because they have poor skeletal support that facilitates soft tissue descent toward the nasolabial folds and oral commissure. Combined malar-submalar implants are the treatment of choice for patients with a type III deficiency. Most of these patients will do poorly with a rhytidectomy alone because of this lack of bony support for the suspended soft tissues. Hence, the result of rhytidectomy in these patients without alloplastic augmentation is usually suboptimal and transient at best.⁹ In addition, some patients with premaxillary retrusion may require custom implants using computer-aided design (CAD) and manufacturing (CAM) techniques that use a high-resolution computed tomography (CT) scan of the face (Fig. 6).¹³

SURGICAL TECHNIQUE

General Guidelines

Available biomaterials for midface augmentation include silicone, polytetrafluoroethylene (Medpor,

Porex Surgical Products, Newnan, GA, USA), and expanded polytetrafluoroethylene (ePTFE). The authors prefer silicone implants because of their flexibility, low infection rates, and ease of insertion and removal.^{9,14–19} Despite the occasional use of the subciliary and lateral facelift approach for implant placement, the transoral approach placing the implant in a subperiosteal pocket offers the most advantages. This approach facilitates an easy insertion and direct visualization of all midface anatomic structures, in particular the infraorbital nerve and inferomedially, the submalar space. There is also the advantage of avoiding external scars, and prevention of the potential downward traction on the lower eyelid postoperatively if a subciliary approach is used. The process of capsular fibrosis facilitates tight adherence of the silicone implants to the facial skeleton in the subperiosteal plane, which protects against postoperative implant migration.^{9,10} However, a potential disadvantage of the transoral approach is the risk of contamination and wound infection due to the implant's exposure to oral flora. Hence, meticulous surgical technique is of paramount importance.

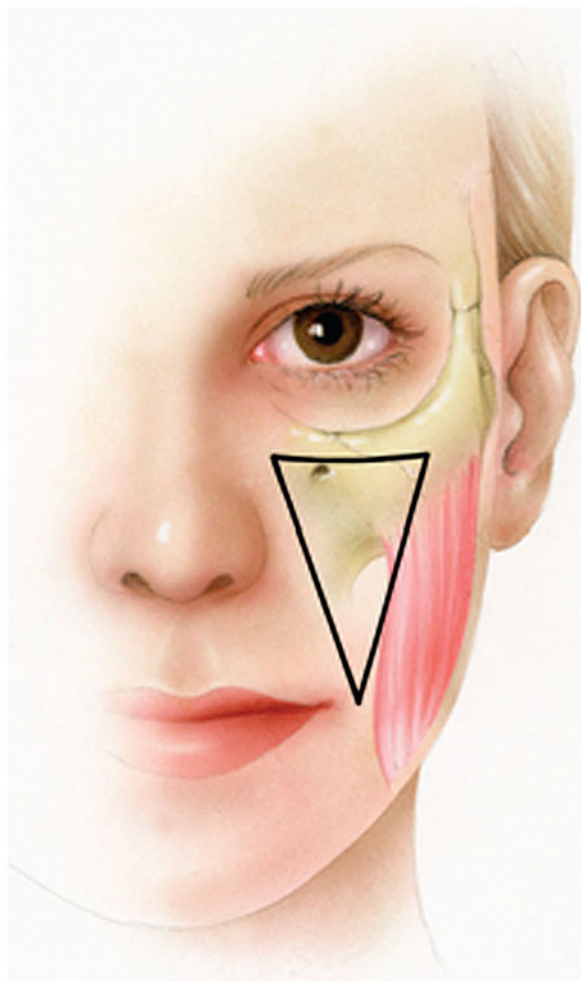


Fig. 5. Submalar triangle. The submalar triangle is bordered superiorly by the zygomatic prominence, laterally by the masseter muscle, and medially by the nasolabial fold; it is the most common area of deficiency with aging. (From Binder WJ, Kim BP, Azizzadeh B. Aesthetic midface implants. In: Azizzadeh B, Murphy MR, Johnson CM, editors. Master techniques in facial rejuvenation. Philadelphia: Saunders; 2007. p. 197–215; with permission.)

The type of facial deformity may determine the sequence of procedures when performing alloplastic augmentation and rhytidectomy concurrently. Type I and III patients who require a major malar component to their midface augmentation procedure or have significant facial asymmetry should have their implants performed before the rhytidectomy. This action allows the surgeon to visualize and thus compensate for the structural changes that may not be apparent after facial edema occurs. In this case, the wound is either left open until the end of the rhytidectomy, or a Penrose drain is placed into the oral incisions to prevent the formation of fluid collections. For most Asian or Latino patients, who require only submalar soft tissue augmentation

because of a type II deformity, the operator can perform the rhytidectomy before placement of the implant. In this case, the advantages include the ability to maintain a dry implant pocket, reduction of subperiosteal bleeding, and the capability of closing the intraoral incision immediately following augmentation to reduce the risk of infection. In either situation, local anesthetic is infiltrated into the tissues in a similar manner as if the implant procedure were performed alone.⁹

Preparation for Surgery

Antibiotic prophylaxis with a broad-spectrum oral antibiotic is started 1 day preoperatively. In the holding area, the patient sits upright, and the crucial areas designated for augmentation are clearly marked (**Fig. 7**). The marked areas should illustrate the midfacial volume deficit, areas of depression, infraorbital nerve axis, and the malar eminence. As a general guide, the most medial border of the typical midface implant may be readily identified by marking the position of the infraorbital nerve, which is parallel to the midpupillary line with the patient staring straight ahead. Then the patient should smile widely to assist in determining the most inferomedial position of the implant and thus ensure that there is no interference with the facial mimetic function. The markings should outline the areas of maximal depression that will receive the maximal augmentation. Once the skin is marked, the patient should be shown a mirror to allow he or she to concur that the proposed changes are satisfactory.⁹ Of importance is that the markings may vary to some degree from the ultimate placement of the implant, and should not be the sole determining factor for implant placement.

Intravenous antibiotics and steroids are used routinely intraoperatively. After the patient has received adequate anesthesia, whether via general anesthesia or intravenous sedation, the surgeon injects 1% or 0.5% lidocaine with epinephrine into the gingival-buccal sulcus and the midface in the subperiosteal plane. To aid in the even dispersion of the local anesthesia and minimize contour irregularities due to injectate overaccumulation, hyaluronidase (Wydase, Wyeth-Ayerst, Philadelphia, PA, USA) is added to the anesthetic solution and the face is then massaged. The operative site is prepared with povidone-iodine (Betadine, Purdue Frederick, Norwalk, CT, USA) from soaked gauze sponges inserted into the gingival-buccal sulcus at the level of the canine fossa for 10 minutes.⁹

Table 1
Patterns of midface deformity

Type	Description of Deformity	Augmentation Required	Implant Type to Use
Type 1	Primary malar hypoplasia: malar bony deficiency with adequate soft tissue. Face lacks desirable features of angular, well-defined cheeks	Requires primarily lateral projection of the malar eminence; results in high-arched, laterally projected cheeks	Malar implant: shell-type extends into the submalar space for more natural result
Type 2	Submalar deficiency; soft tissue deficiency with adequate malar bone. Face appears dull and flat; most common deficiency of the aging face	Requires anterior projection of the midface and submalar hollow; restores lost midface volume characteristic of a more youthful face	Submalar implant: placed over the anterior maxilla and the masseter tendon, extending into the submalar space
Type 3	Combined malar and submalar deficiency: volume-deficient face with inadequate bony and soft tissues. Marked by premature signs of aging	Requires both anterior and lateral projection of the entire midface and submalar regions	Combined malar-submalar implant: lateral (malar) and anterior (submalar) projection to fill a large midfacial void

From Binder WJ, Azizzadeh B. Malar and submalar augmentation. *Facial Plastic Surg Clin North Am* 2008;16(1):17; with permission.

Incision and Dissection of the Malar Eminence

Due to the plasticity of the mucosa, insertion of the implant requires only a 3-mm stab incision in the gingival-buccal sulcus over the lateral canine fossa and maxillary buttress (**Fig. 8**). The incision is made in an upward oblique direction, and is carried immediately and directly to the maxillary bone. Bleeding is minimized by compressing the mucosa against the bone. An inferior cuff of mucosa of a minimum of 1 cm facilitates closure at the end of the procedure. Removing dentures during the operation is unnecessary, because they do not interfere with insertion of the implant, and actually direct placement of the incision above the denture to the correct location.⁹

After the initial incision, the periosteum of the anterior maxilla is elevated superiorly and laterally (**Figs. 9 and 10**). Following the preoperative markings, the surgeon uses his or her external free hand to provide crucial guidance to the direction and extent of dissection. The subperiosteal elevation is initiated with the Joseph elevator, which is changed quickly to a broader 10-mm Tessier elevator (**Fig. 11**). This technique enables a greater degree of safety and ease of periosteal dissection. The infraorbital nerve should be identified carefully if the proposed implant is large or bears a significant medial

component. This identification prevents placing the implant over the foramen.⁹

Dissection then is extended laterally to the malar-zygomatic junction and zygomatic arch. The subperiosteal plane is used for dissection, particularly over the lateral zygoma, where branches of the facial nerve traverse just superficial to this plane (**Fig. 12**). Injuring the temporal branch of the facial nerve can be avoided by using gentle blunt dissection over the mid-zygomatic arch, ensuring the dissection is on bone and within the subperiosteal plane. Emphasis is placed on using a broad elevator, which is far safer than a delicate, thin instrument that could more readily puncture the periosteum laterally because of limited visibility during the procedure.⁹

Exposure of the Submalar Triangle and Creation of an Implant Pocket

Patients with type II or III midface deficiencies require exposure of the submalar space. This anatomic depression extends about 3 cm beneath the zygoma. To expose this region, the subperiosteal dissection is continued inferiorly below the zygoma and over the superior tendinous insertion of the masseter muscle. Gentle elevation of the overlying soft tissue from the

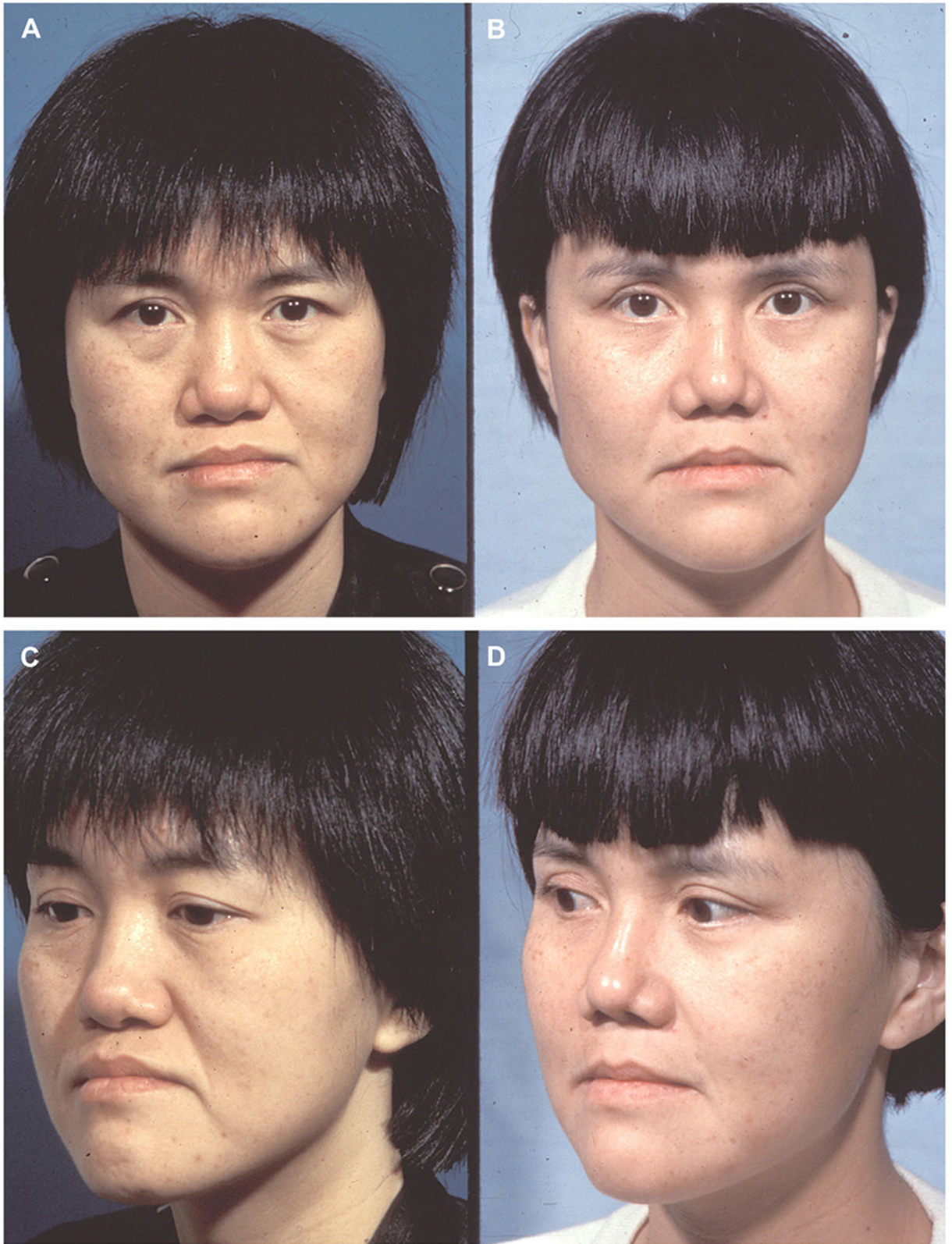

Fig. 6. Custom premaxillary and midfacial implant. Preoperative photos (A, C, E) in this patient represent a premaxillary retrusive midface commonly found in the Asian population. Postoperative photos (B, D, F) reveal significant improvement in premaxillary projection and midfacial contouring.

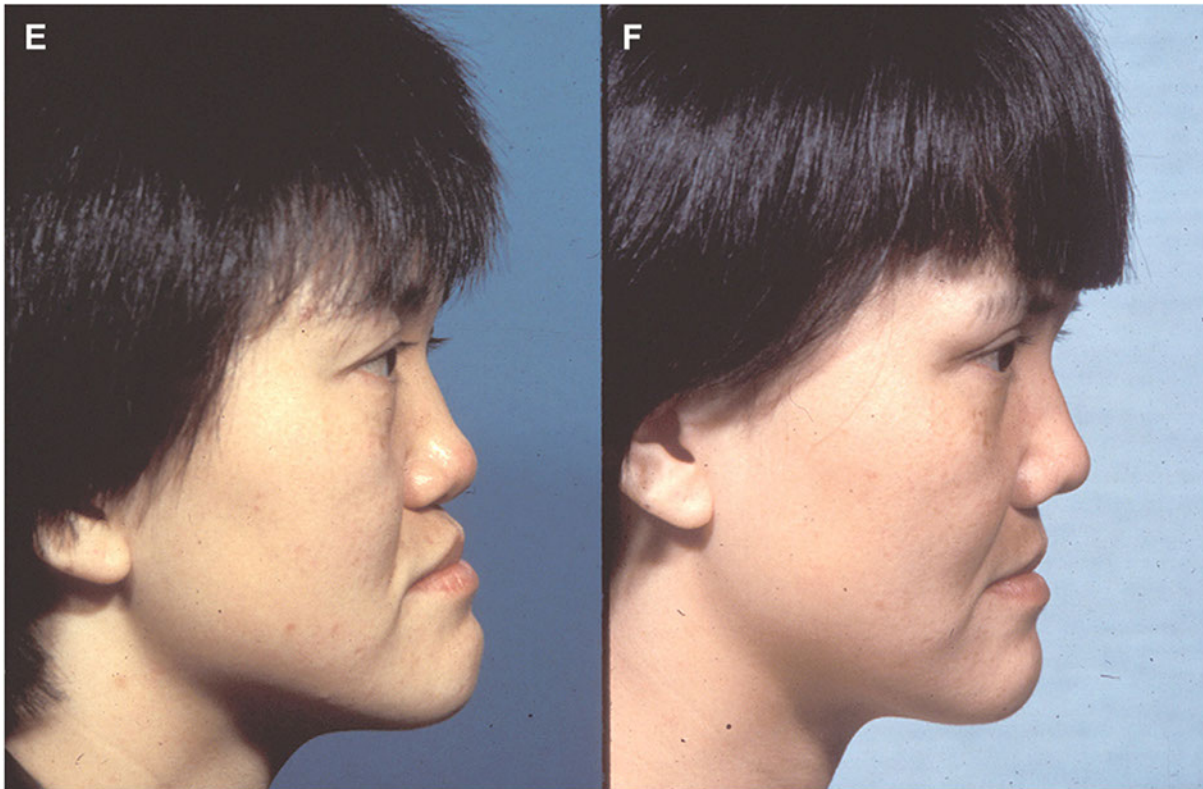

Fig. 6. (continued)

deeper plane of the tendon facilitates visualization of the glistening white tendinous attachment of the masseter (**Fig. 13**). The muscle attachments are not divided because they serve as a critical platform for the inferior portion of the submalar

implant. The submalar space narrows significantly posteriorly, and is not accessed easily. Careful dissection of the posterior limit can be accomplished by advancing a blunt elevator along the inferior border of the zygomatic arch. Masseter

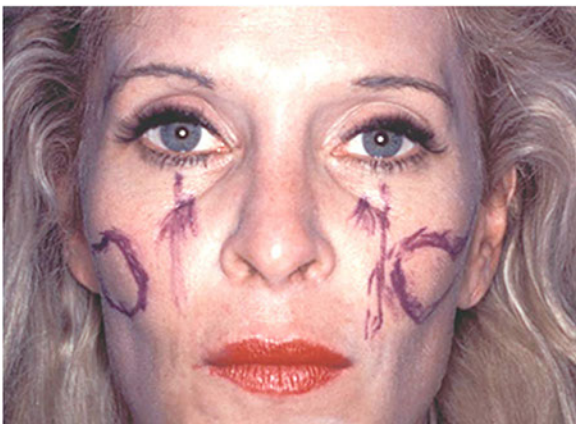

Fig. 7. Preoperative markings. With the patient sitting upright, the areas of midface deficiency requiring augmentation are marked. The infraorbital nerve axis along the midpupillary line designates the medial border of dissection. (From Binder WJ, Kim BP, Azizzadeh B. Aesthetic midface implants. In: Azizzadeh B, Murphy MR, Johnson CM, editors. Master techniques in facial rejuvenation. Philadelphia: Saunders; 2007. p. 197–215; with permission.)

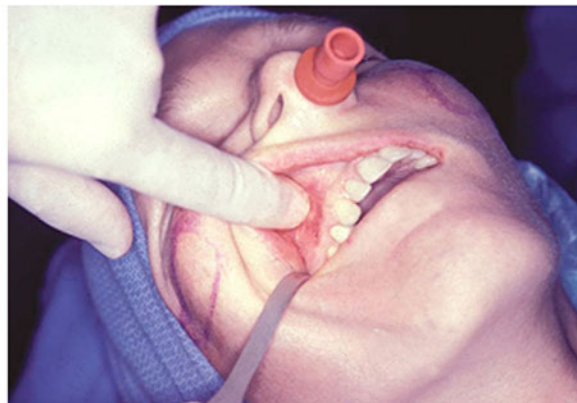

Fig. 8. Oral incision. The gingival-buccal incision is made over the lateral canine fossa. Only 3 mm is required for adequate dissection and exposure of the midface skeleton. A 1- to 1.5-cm cuff of gingiva is maintained inferiorly. (From Binder WJ, Kim BP, Azizzadeh B. Aesthetic midface implants. In: Azizzadeh B, Murphy MR, Johnson CM, editors. Master techniques in facial rejuvenation. Philadelphia: Saunders; 2007. p. 197–215; with permission.)

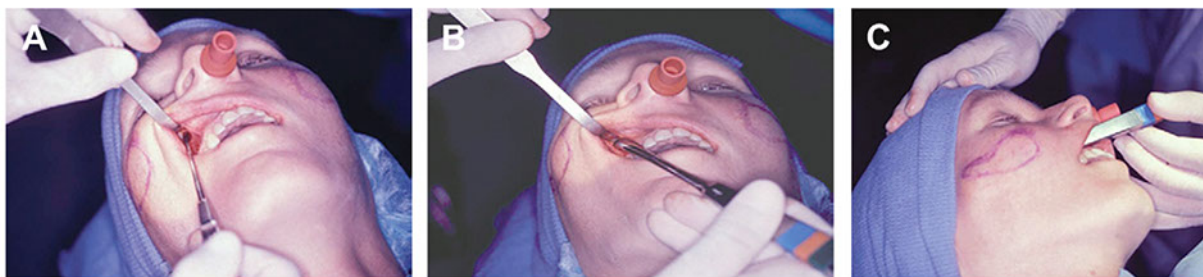


Fig. 9. Periosteal elevation. The periosteum is elevated over the maxilla superiorly and laterally. The borders of the dissection are the masseteric tendon and infraorbital rim (A–C). (From Binder WJ, Kim BP, Azizzadeh B. Aesthetic midface implants. In: Azizzadeh B, Murphy MR, Johnson CM, editors. Master techniques in facial rejuvenation. Philadelphia: Saunders; 2007. p. 197–215; with permission.)

muscle contraction at its superior border tends to be limited, thereby preventing postoperative implant displacement.⁹

A pocket large enough to accommodate the appropriate implant is created over the malarzygomatic complex and submalar triangle. The dissected space always should be sufficiently larger than the implant so that the implant can fit into it easily without being compressed by the surrounding tissues, particularly posteriorly. Displacement of the implant can occur if an implant is forced into an inadequately sized pocket, or if the posterolateral portion of the pocket is poorly exposed. In the latter case, constriction of the area will push the implant anteriorly, causing it to migrate or extrude. When the

implant is situated in the dissected space, it should sit passively and one generally should be able to move it at least 3 to 5 mm in all directions. After closure of the wound, even after a large pocket is made, the periosteum and soft tissues contract; the pocket immediately closes down around the implant, and the dead space usually is obliterated within 24 to 48 hours.^{9,12}

Insertion of the Implant

Preoperative facial analysis along with the type of midface deficiency and the patient's desires typically determines the location and the size of the implant. Selecting the appropriate midface implant should take into account the bulk of the overlying

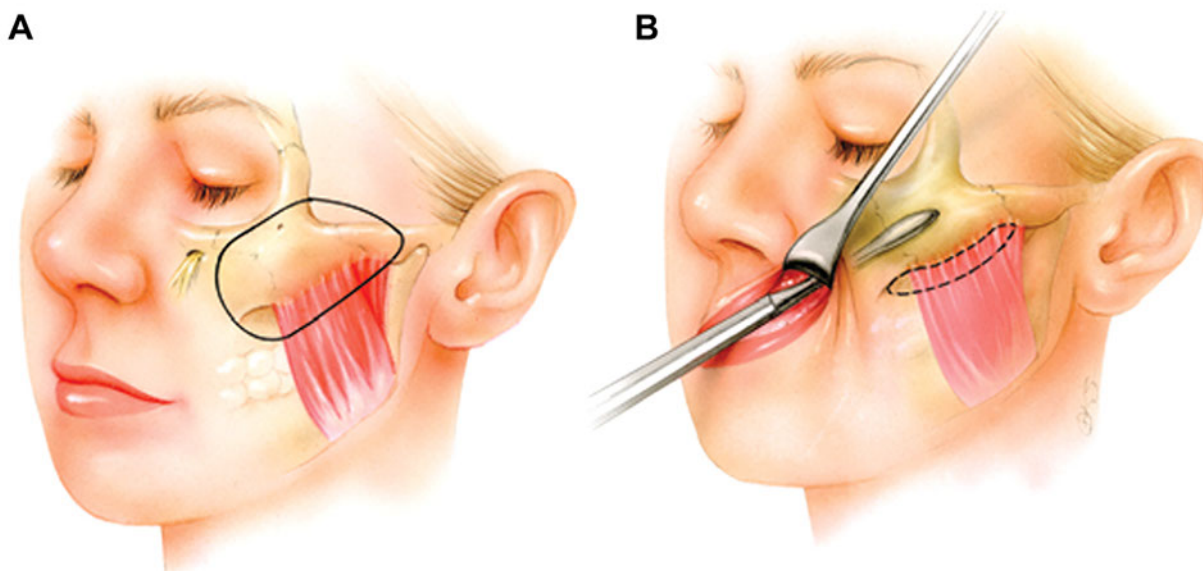


Fig. 10. Periosteal elevation. (A) Initial dissection over the anterior maxillary wall. (B) The stippled area represents the submalar dissection over the masseteric tendon. The dashed line represents the area that generally is elevated. (From Binder WJ, Kim BP, Azizzadeh B. Aesthetic midface implants. In: Azizzadeh B, Murphy MR, Johnson CM, editors. Master techniques in facial rejuvenation. Philadelphia: Saunders; 2007. p. 197–215; with permission.)

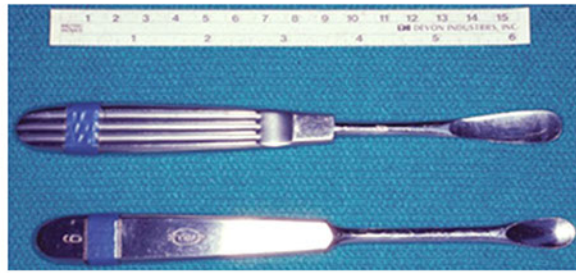


Fig. 11. Instruments: periosteal elevators. Periosteal elevation begins with the Joseph elevator to gain initial access, but most of the dissection should be performed with the 10-mm Tessier elevator. (From Binder WJ, Kim BP, Azizzadeh B. Aesthetic midface implants. In: Azizzadeh B, Murphy MR, Johnson CM, editors. Master techniques in facial rejuvenation. Philadelphia: Saunders; 2007. p. 197–215; with permission.)

tissue and formation of the fibrous capsule. Therefore, it is best to choose an implant that is marginally smaller than the desired volume changes. In type II deficiencies, submalar implants generally rest over the anterior face of the maxilla. Type III deformities use combined malar-submalar implants that cover both the malar bony eminence and the submalar triangle. To achieve the desired facial contour changes, positioning an implant in the submalar triangle typically requires greater

experience and judgment than is necessary for implants placed over the malar eminence. Regardless of the type of augmentation, however, the end aesthetic result should achieve the desired changes in facial contour and generally correspond to the preoperative facial markings rather than to the underlying skeletal anatomy.⁹

Implants should be soaked in antibiotic solution (bacitracin 50,000 U/L) at the start of the procedure and allowed to remain there until the time

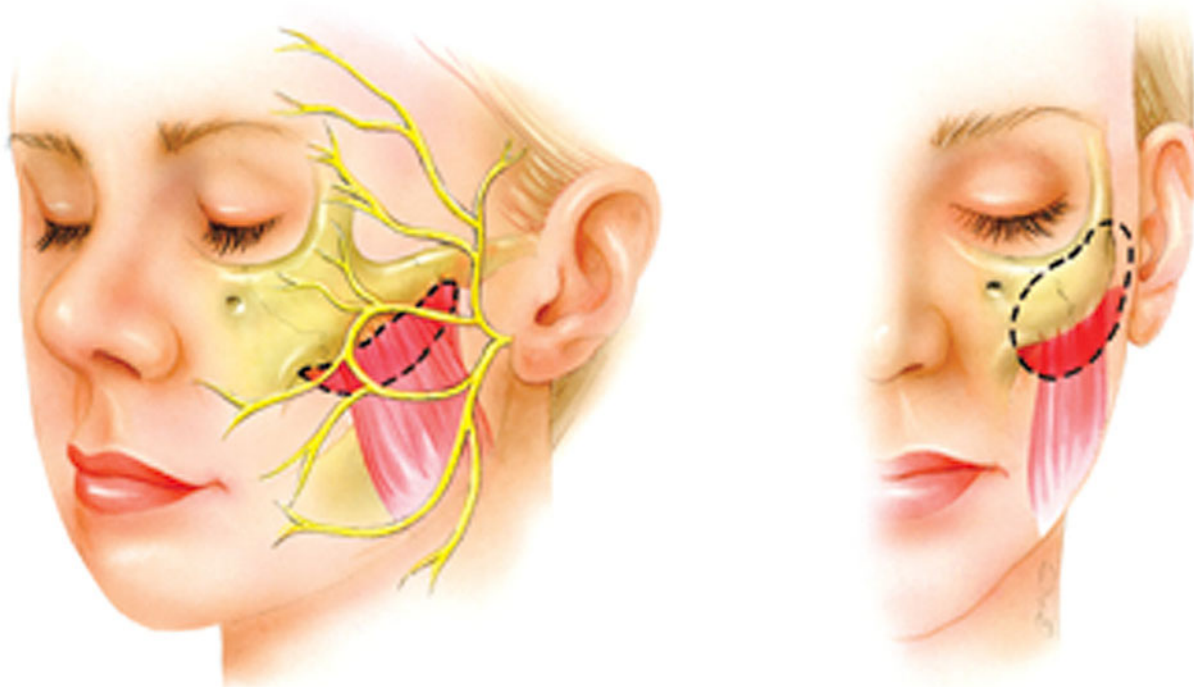


Fig. 12. Facial nerve branches in the region of dissection. It is crucial to dissect in the subperiosteal plane over the zygomatic arch, to avoid injury to the temporal branch of the facial nerve. The use of a broad elevator will help prevent perforation of the periosteum in this region. The buccal branches are also at risk if the region over the masseter is dissected aggressively. (From Binder WJ, Kim BP, Azizzadeh B. Aesthetic midface implants. In: Azizzadeh B, Murphy MR, Johnson CM, editors. Master techniques in facial rejuvenation. Philadelphia: Saunders; 2007. p. 197–215; with permission.)

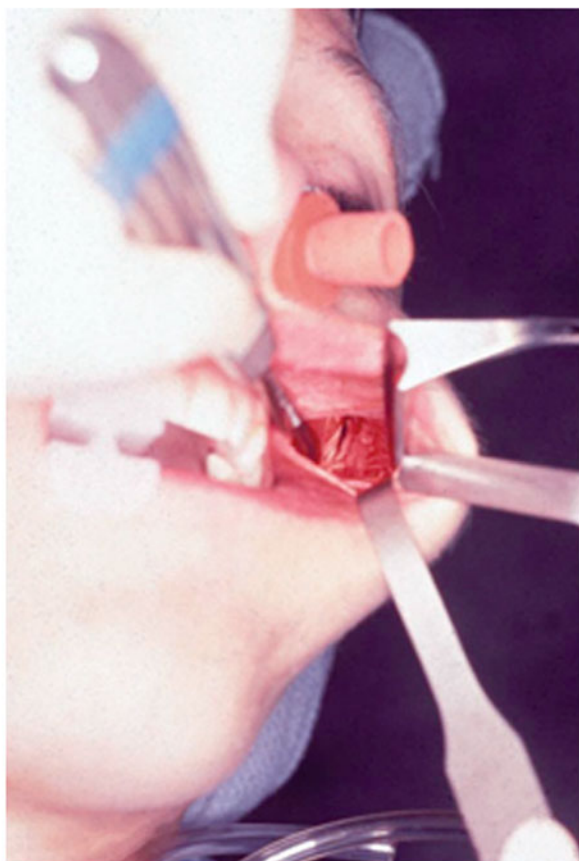


Fig. 13. Submalar triangle and masseteric tendon. The lateral aspect of the dissection will be over the masseteric tendon, inferior to the lateral zygomatic arch. In this region, the soft tissues are elevated gently over the glistening white fibers of the tendon, allowing placement of the tail of the submalar implant. (From Binder WJ, Kim BP, Azizzadeh B. *Aesthetic midface implants*. In: Azizzadeh B, Murphy MR, Johnson CM, editors. *Master techniques in facial rejuvenation*. Philadelphia: Saunders; 2007. p. 197–215; with permission.)

of insertion. A “no-touch” technique should be used, if possible, to ensure minimal implant handling and reduce the risk of contamination. The surgeon and assistant should also ensure that any powder residue is washed off the surgical gloves. An assortment of different implant sizes and shapes should be available in the operating room, and the surgeon must be capable of customizing the implants via carving (**Fig. 14**). Sizers should be used to determine and confirm the appropriate implant size and shape. Modifications to the implant shape then can compensate for overall size, shape, and facial asymmetry. Shaving an implant as little as 1 mm can impact the final aesthetic results significantly, especially in patients who have thin facial skin,⁹ although this is less of a concern in the

Asian and Latino population given their thicker skin and soft tissue.

Assessing for facial asymmetry is critical following insertion of the implants. The operator can use a ruler to measure the distances from the medial border of the implants to the midline. Preexisting facial asymmetry can pose significant challenges and require exquisite attention to the bony and soft tissue topography. In these cases, each implant may need to be contoured or positioned asymmetrically. In addition, patients who have thin skin or prominent facial skeletons may require modifications in the implants, so as to reduce any edges or contours of larger, thicker implants that would otherwise be palpable or cause visible irregularities. Again, this may be less of a concern in the Asian and Latino population. After placing both implants, the surgeon may stand at the head of the table to acquire a more precise assessment of contour asymmetry.⁹

Securing the Implant

To prevent postoperative implant migration, several methods can be used to secure the implant following proper placement. Larger malar or combined malar-submalar implants are not prone to migration and may not require fixation due to their positioning over the zygoma. Nonetheless, it is the authors' recommendation to apply external suture fixation using 1 of 2 techniques. In the indirect lateral suture fixation method, long (10 in [25.4 cm]) double-armed Keith needles on 0-0 silk sutures are passed through the lateral end of the implant (**Fig. 15**). The needles are inserted into the wound and directed posterolaterally; then they exit the temporal region behind the hairline. The implant is then placed into the final position, and the sutures are tied over a cotton roll bolster. This technique works best with malar shell implants in type I deformities by applying a superolateral tension over the implants and maintaining their position over the bony malar-zygomatic eminence.⁹

The second suture method, the direct external fixation method (**Fig. 16**), is better suited for submalar and combined malar-submalar facial implants in type II and III deformities. This method is also the preferred technique when the implants are excessively mobile within the wound pocket or when asymmetrical placement of implants becomes necessary. Midface implants usually have 2 preformed fenestrations, of which the position of the medial fenestration should be marked on the external skin while the implant resides in the subperiosteal pocket. Using

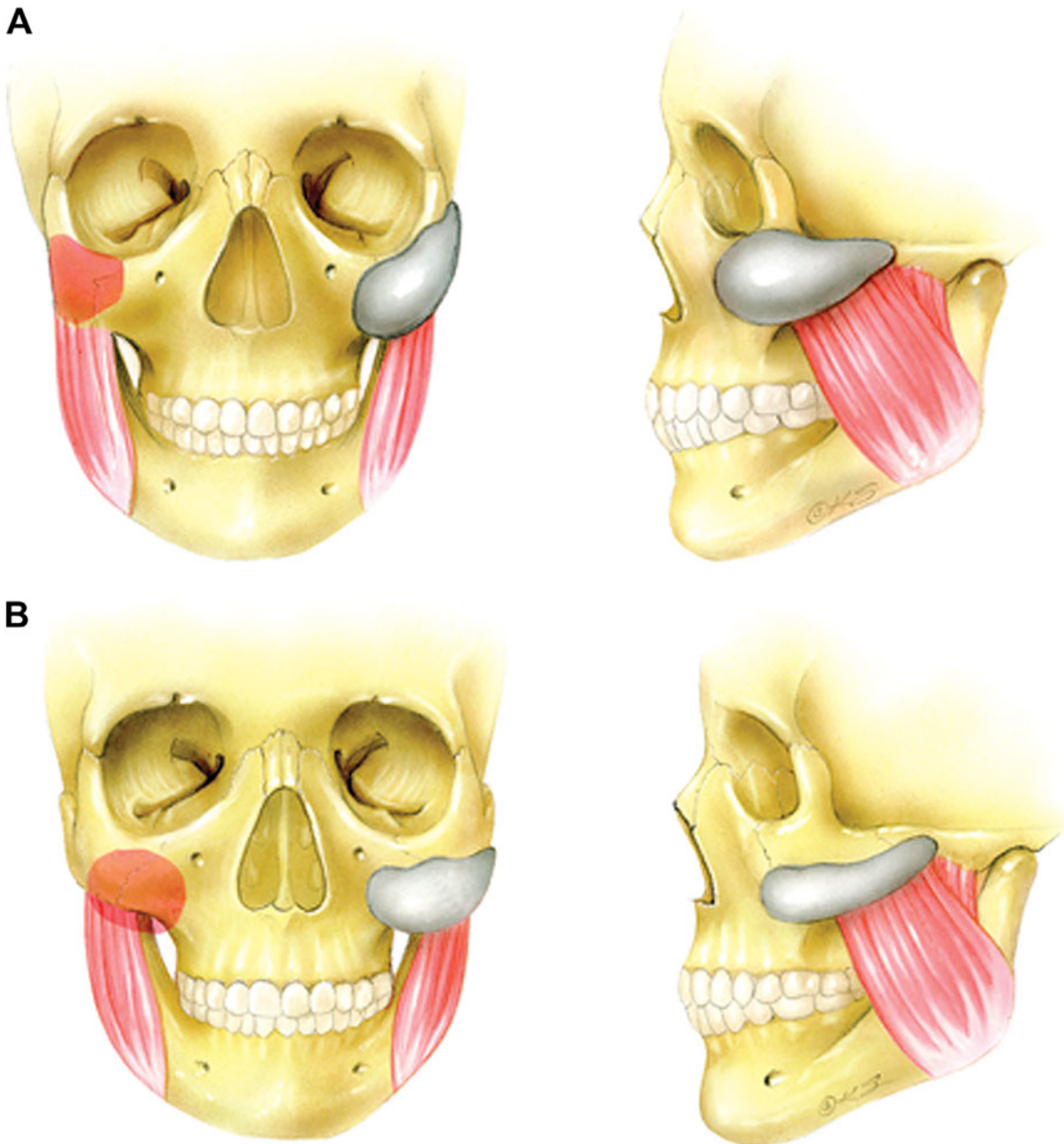


Fig. 14. Implant placement. Malar shell implants for type I deformity rest on top of the malar and zygomatic bone in a more superior and lateral position (A). Submalar implants for type II deformity generally lie over the anterior face of the maxilla (B).

a right-angle clamp to push the implant upward, underneath the fenestration, the holes can be located, and the resulting external protuberance can be marked on the skin. Symmetry can be confirmed by measuring and comparing the distance of each marking to the midline. After marking the medial fenestrations, the skin should be marked to coincide with the location of the lateral fenestration of the implant. This procedure can be done by first removing the implants and

placing them on top of the midface. The implants then are positioned to coincide with the desired contour and preoperative markings. The second skin mark is applied to match the location of the lateral fenestration of the implant. After passing double-armed 3-0 silk sutures through the medial and lateral fenestrations with the loop around the deep surface of the implant, the needles are placed into the wound pocket and passed perpendicularly through the skin

C

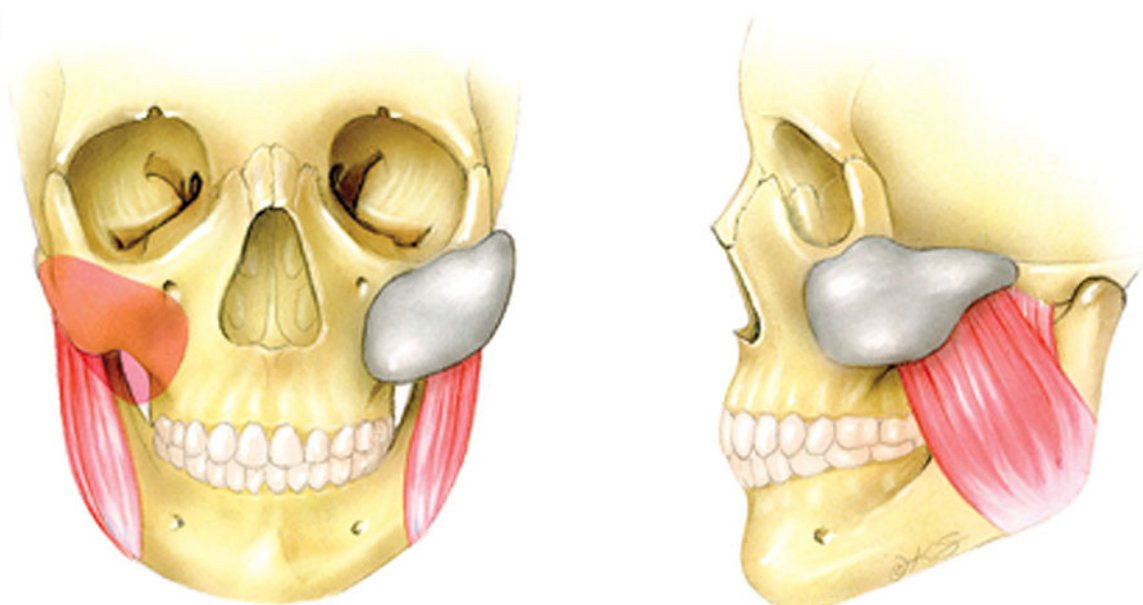


Fig. 14. (continued) Combined malar-submalar implants for type 3 deformity will cover both the malar bony eminence and the submalar triangle (C). (From Binder WJ, Kim BP, Azizzadeh B. Aesthetic midface implants. In: Azizzadeh B, Murphy MR, Johnson CM, editors. Master techniques in facial rejuvenation. Philadelphia: Saunders; 2007. p. 197–215; with permission.)

markings corresponding to each fenestration. The implant is then delivered into the pocket, ensuring proper position and symmetry. Finally, the sutures are tied gently over cotton roll bolsters overlying the anterior cheek. These bolsters aid

in compressing the midface, reduce any potential dead space, and prevent fluid from collecting in the subperiosteal pockets. The external sutures and bolsters may be removed 24 to 48 hours postoperatively.⁹

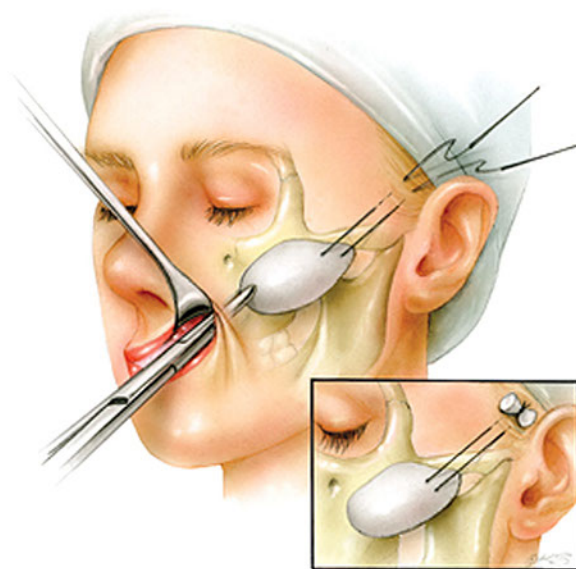


Fig. 15. Indirect lateral suture fixation. This method is best for malar shell implants (type I deformity) by applying a superolateral tension on the implants and maintaining their position over the bony malar-zygomatic eminence. Long (10 in [25.4 cm]) double-armed Keith needles on 0-0 silk suture are passed through the lateral end of the implant directed posterolaterally, exiting the temporal region behind the hairline. The implant is then placed into the final position, and the sutures are tied over a cotton roll bolster. (From Binder WJ, Kim BP, Azizzadeh B. Aesthetic midface implants. In: Azizzadeh B, Murphy MR, Johnson CM, editors. Master techniques in facial rejuvenation. Philadelphia: Saunders; 2007. p. 197–215; with permission.)

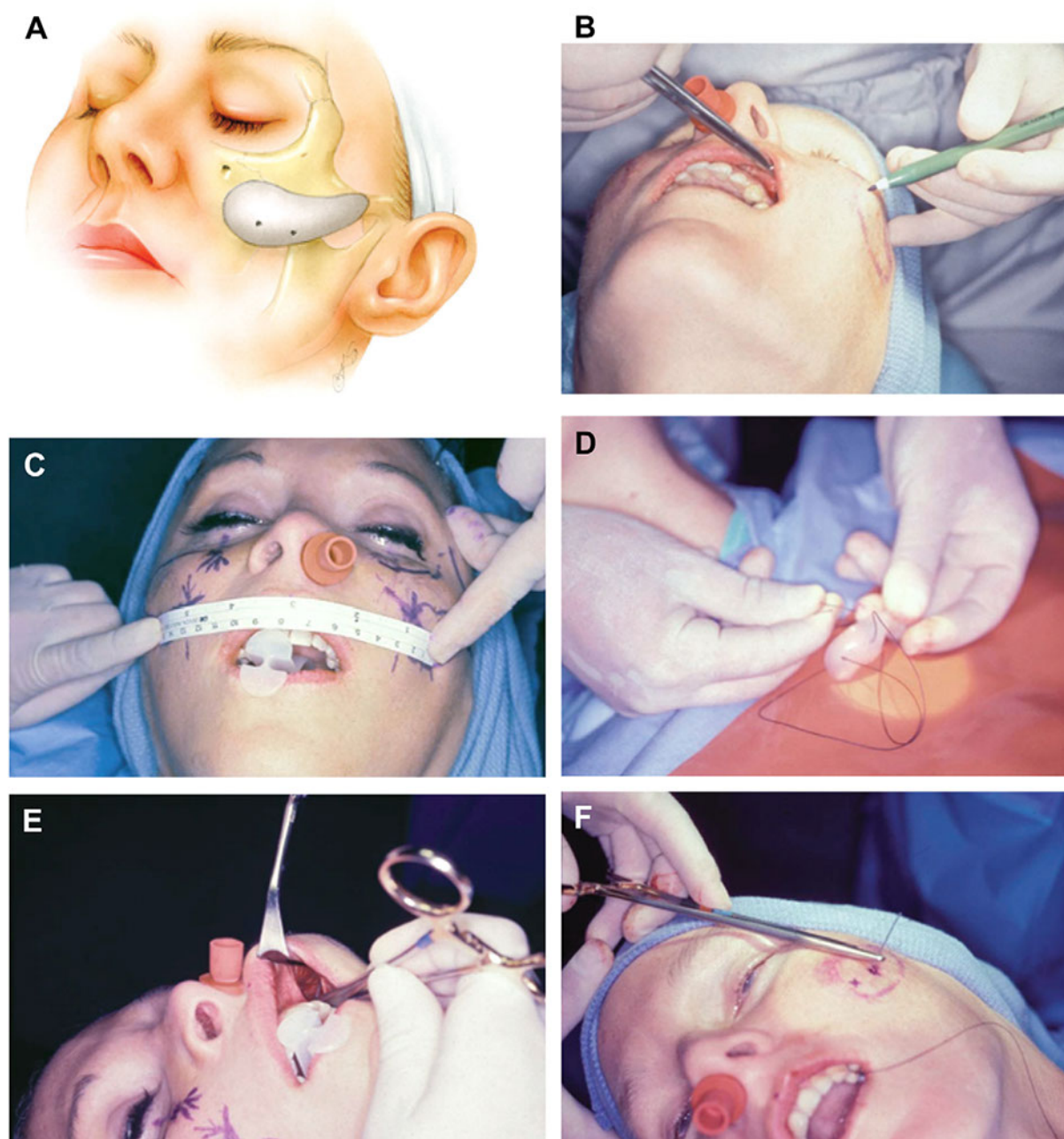


Fig. 16. Direct external fixation. Direct external fixation allows precise fixation and is suited best for submalar and combined implants in type II and type III patients. (A) The implant is adjusted in the pocket to obtain the exact desired location. (B) A right-angle clamp is used to mark the location of the implant fenestrations by pressing behind the fenestration outward through the facial skin and marking the area of protuberance. A second fenestration mark is placed to ensure adequate orientation. (C) Symmetric placement of marking is checked. (D–F) The suture needles are passed through the fenestration points and passed perpendicular through the skin markings corresponding to each fenestration.

Implants can also be secured using internal suture fixation and by attaching the medial aspect of the implant to the periosteum and soft tissues. In addition, screws can be used to fix the implant, but only in those cases where it is in an acceptable position to accept the screw over the lateral buttress and not in the canine fossa. If the implant is placed before rhytidectomy, the oral incision is

reopened to fix the implant with external sutures. Intraoral Penrose drains may be placed if necessary.⁹

Wound Closure and Dressing

Intraoral incisions are irrigated copiously with antibiotic solution before closing them in one layer using chromic sutures. The external suture

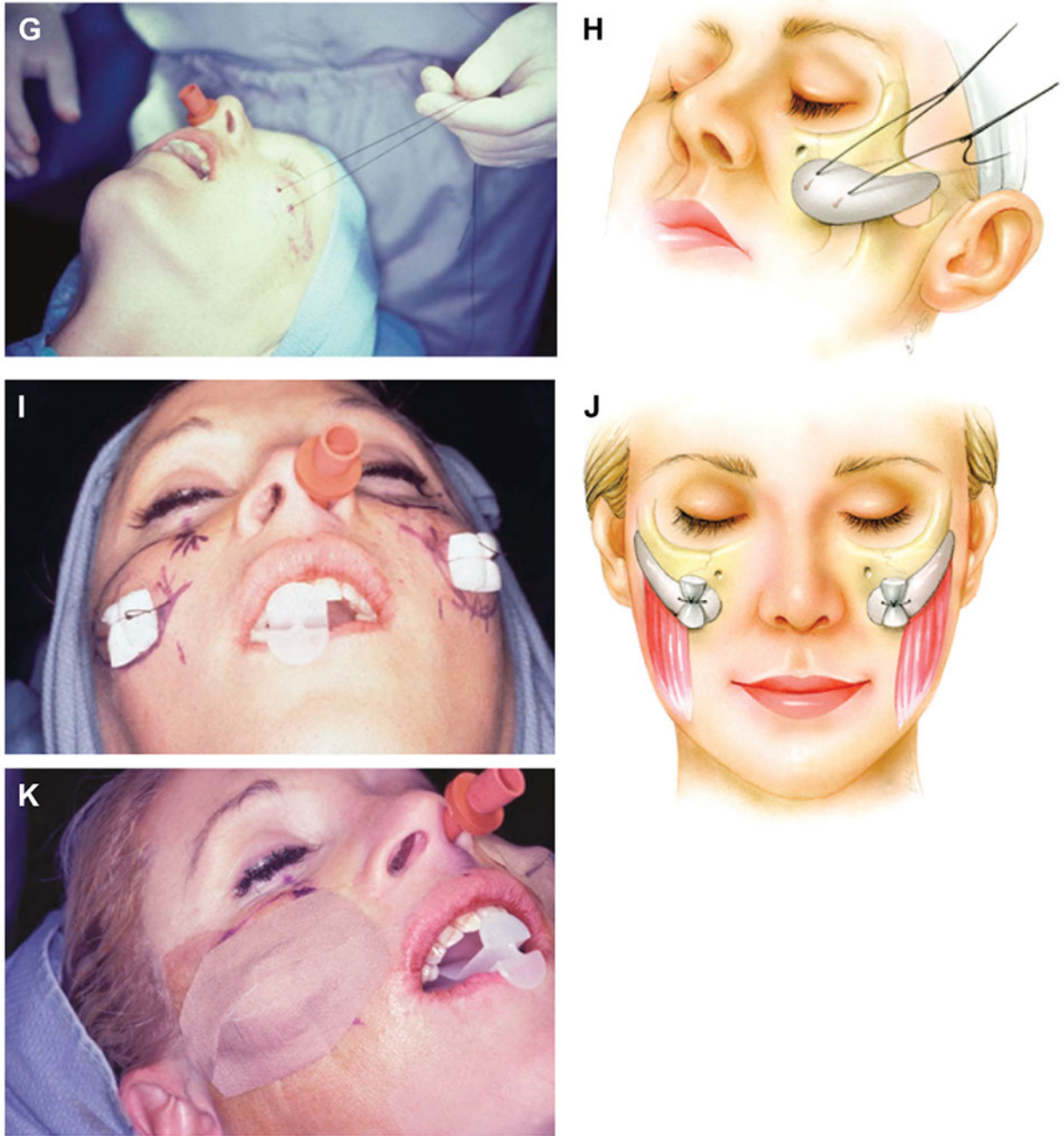

Fig. 16. (continued) Symmetric placement of marking is checked. (G, H) The suture needles are passed through the fenestration points and passed perpendicular through the skin markings corresponding to each fenestration. (I, J) After ensuring precise location and adequate fixation of the midface implants, the sutures are tied over a cotton roll bolster. (K) Benzoin and a flexible band aid then can be placed over the bolster. (From Binder WJ, Kim BP, Azizzadeh B. Aesthetic midface implants. In: Azizzadeh B, Murphy MR, Johnson CM, editors. Master techniques in facial rejuvenation. Philadelphia: Saunders; 2007. p. 197–215; with permission.)

bolsters are covered with bandages, and an elastic facial dressing is applied and left in place for 24 hours. A full elastic garment dressing that allows even compression of the midface is preferred (**Fig. 17**). As the elastic dressing applies adequate pressure to obliterate the pocket posterior to the implant, the suture bolster closes the

midface pocket anterior to the implant. Patients are encouraged to use this elastic dressing after the bolsters are removed for an additional 24 to 48 hours. If a concomitant rhytidectomy is performed and the bolsters are in place, a lighter neck and facial dressing (which also mildly compresses the midface) comprised of cotton



Fig. 17. Elastic facial dressing. A full-face compression garment can help reduce postoperative edema and fluid collection. (From Binder WJ, Kim BP, Azizzadeh B. Aesthetic midface implants. In: Azizzadeh B, Murphy MR, Johnson CM, editors. Master techniques in facial rejuvenation. Philadelphia: Saunders; 2007. p. 197–215; with permission.)

and cling is placed rather than the elastic compression dressing.⁹

Postoperative Care

Patients may recover at home or in an aftercare facility. Patients are recommended to use ice packs for 3 to 4 days and sleep with the head in an elevated position. Antibiotics, analgesics, and antiemetic medications are prescribed to all patients. The first follow-up visit occurs on postoperative day 1 at which time the facial dressings, bolsters, and any drains are removed. The mask may be reapplied and worn for another 24 to 48 hours, which helps reduce postoperative edema and overall recovery time. Patients are typically able to resume nonstrenuous routine activity 3 to 5 days postoperatively. In general, approximately 80% to 85% of the edema resolves within 3 to 4 weeks, and the remaining 15% to 20% subsides over the following 6 months.⁹

Complications

Malposition and errors in implant selection are the most frequent complications of facial implant

augmentation.^{9,14,20} Incorrect positioning, insufficient pocket size, or inadequate fixation of the implant can lead to postoperative displacement. During the immediate postoperative period, patients should be assessed within 48 to 72 hours after surgery to ensure against significant facial asymmetry. Implant extrusion is extremely rare, and usually occurs through the intraoperative incision because of inadequate dissection of the posterolateral pocket.^{9,20}

Augmentation using alloplastic silicone implants has an estimated infection rate of approximately 1%.^{9,20} Tactics to minimize the risk of infection include soaking the implant in antibiotic solution, irrigating the wound, and avoiding blood and fluid accumulation in the surgical pocket. Other complications include bleeding, hematoma, and seroma. Placement of drains can help in preventing fluid collections, especially when concomitant rhytidectomy is performed or when there is excessive bleeding intraoperatively. Injury to the infraorbital nerve can occur, and may result in infraorbital numbness lasting from days to weeks postoperatively; this is rarely permanent. Other potential risks include injury to the frontal branch of the

Box 1**Pearls and pitfalls**

1. Have the patient smile broadly to assist in determining the most inferomedial position of the implants and to ensure that there is no interference with facial mimetic function.
2. A 3-mm stab incision is made over the lateral canine fossa in the gingival-buccal sulcus with compression of the mucosa to minimize bleeding.
3. The subperiosteal elevation is initiated with a Joseph elevator, which is changed quickly to a broader 10-mm Tessier elevator to avoid excessive dissection, stretching, and traction in the area of the infraorbital nerve. The nerve should be carefully identified if the implant is large or has a large medial component, to prevent placing the implant over the foramen.
4. The subperiosteal plane must be maintained over the zygomatic arch by using gentle blunt dissection with the Tessier elevator over the mid-arch to avoid injury to the temporal branch of the facial nerve.
5. The soft tissue over the masseter must be elevated gently without dividing the muscle or its tendinous attachments to avoid injury to the buccal branches of the facial nerve and to preserve the platform for the inferior part of the implant.
6. The dissected pocket should always be sufficiently larger than the implant, and the surgeon should be able to move it at least 3 to 5 mm in all directions.
7. It is preferable to "undercorrect" or choose an implant that is marginally smaller than the desired volume changes to account for the formation of the fibrous capsule and the bulk of the overlying tissue.
8. For larger malar implants an external, indirect, lateral suspension suture technique is preferable to apply superolateral tension on the implants and maintain their position over the bony malar-zygomatic eminence.
9. For submalar or combined malar-submalar implants, excessive mobility of the implants, or when asymmetrical placement of implants is necessary, the direct external fixation method is preferable.
10. The medial fenestration should be marked on the skin while the implant resides in the pocket. Symmetry between the 2 sides can be confirmed by comparing and measuring the distance of each marking to the midline. The lateral marking is then made with implants placed on top of the midface in the desired position.

facial nerve during dissection of the zygomatic arch and injury to the buccal branch with overly aggressive masseter dissection.

SUMMARY

Alloplastic midface implantation in the Asian and Latino patient presents various challenges and opportunities for the facial plastic surgeon. Their thicker skin, increased facial adipose tissue, and decreased facial skeletal support make them ideal candidates for anterior projection and support using midface implants. Cultural factors must also be considered in patients for whom prominent malar eminences are aesthetically displeasing. Therefore, critical analysis of the patient's face along with open and precise communication between patient and surgeon can lead to optimal patient satisfaction using this powerful modality to enhance the midface (**Box 1**).

REFERENCES

1. US Census Bureau. Census 2000 Modified Race Data. 2002.
2. Lam SM. Aesthetic facial surgery for the Asian male. *Facial Plast Surg* 2005;21(4):317–23.
3. Shirakabe Y, Suzuki Y, Lam SM. A new paradigm for the aging Asian face. *Aesthetic Plast Surg* 2003;27(5):397–402.
4. Sykes JM. Management of the aging face in the Asian patient. *Facial Plast Surg Clin North Am* 2007;15(3):353–60, vi–vii.
5. Lam SM. Aesthetic strategies for the aging Asian face. *Facial Plast Surg Clin North Am* 2007;15(3):283–91, v.
6. Cobo R. Facial aesthetic surgery with emphasis on rhinoplasty in the Hispanic patient. *Curr Opin Otolaryngol Head Neck Surg* 2008;16(4):369–75.
7. Molina F. Aesthetic facial osteotomies in Latin Americans. *Clin Plast Surg* 2007;34(3):e31–6.
8. Shire JR. Preface in "Facial Implants". *Facial Plast Surg Clin North Am* 2008;16(1):ix–x.
9. Binder WJ, Azizzadeh B. Malar and submalar augmentation. *Facial Plast Surg Clin North Am* 2008;16(1):11–32, v.
10. Binder WJ, Schoenrock LD, Terino EO. Augmentation of the malar-submalar/midface. *Facial Plast Surg Clin North Am* 1994;2(3):265–83.
11. Psillakis JM, Rumley TO, Carmagos A. Subperiosteal approach as an improved concept for correction of the aging face. *Plast Reconstr Surg* 1988;82(3):383–94.

12. Binder WJ. A comprehensive approach for aesthetic contouring of the midface in rhytidectomy. *Facial Plast Surg Clin North Am* 1993;1(2):231–55.
13. Binder WJ. Custom-designed facial implants. *Facial Plast Surg Clin North Am* 2008;16(1):133–46, vii.
14. Wilkinson TS. Complications in aesthetic malar augmentation. *Plast Reconstr Surg* 1983;71(5):643–9.
15. Silver WE. The use of alloplast material in contouring the face. *Facial Plast Surg* 1986;3:81–98.
16. Whitaker LA. Aesthetic augmentation of the malar-midface structures. *Plast Reconstr Surg* 1987;80(3):337–46.
17. Prendergast M, Schoenrock LD. Malar augmentation. Patient classification and placement. *Arch Otolaryngol Head Neck Surg* 1989;115(8):964–9.
18. Binder WJ. Submalar augmentation. An alternative to face-lift surgery. *Arch Otolaryngol Head Neck Surg* 1989;115(7):797–801.
19. Terino EO. Alloplastic facial contouring by zonal principles of skeletal anatomy. *Clin Plast Surg* 1992;19(2):487–510.
20. Rubin PJ, Yaremchuk MJ. Complications and toxicities of implantable biomaterials used in facial reconstructive and aesthetic surgery: a comprehensive review of the literature. *Plast Reconstr Surg* 1997;100(5):1336–53.